

Case Report

Report of rare case of dermatofibrosarcoma protuberans in the buccal mucosa: review of diagnostic, histopathological and immunohistochemical criteria

Amanda Katarinny Goes Gonzaga¹, Angélica Lopes Cordeiro Mandú¹, Alexandre Oliveira Sales², Ana Miryam Costa Medeiros¹, Rodrigo Rodrigues Rodrigues³, Patrícia Teixeira Oliveira¹, Adriano Rocha Germano³, Éricka Janine Dantas Silveira¹

Dermatology Online Journal 22 (10): 4

¹ Postgraduate Program, Oral Pathology, Federal University of Rio Grande do Norte, Natal, RN, Brazil

² Liga Norte Riograndense Contra o Câncer, Natal, RN, Brazil

³ Oral and Maxillofacial Surgery and Traumatology Residency, Dentistry Department, Federal University of Rio Grande do Norte, Natal, RN, Brazil

Correspondence:

Amanda K. G. Gonzaga, DDS, Master's Student
Department of Dentistry, Oral Pathology, Federal University of Rio Grande do Norte
Avenue Senador Salgado Filho, 1787
Lagoa Nova, Natal-RN
59056-000, Brazil
Tel. +55 84 99294608
amandaggonzaga@gmail.com

Abstract

Dermatofibrosarcoma protuberans (DFSP) is an uncommon intermediate-grade soft tissue sarcoma. The tumor is found preferentially on the trunk, whereas the head and neck region are affected in only 10% to 15% of cases. We report the case of a 44-year-old woman with a 5-month history of an asymptomatic, firm, yellow nodule in the mucosa of the right cheek measuring 2.5 cm. The clinical diagnosis was lipoma and an excisional biopsy was obtained. Histopathological analysis revealed a proliferation of spindle-shaped mesenchymal cells arranged in interlacing fascicles amidst fibrous stroma. Low mitotic activity (2 mitoses per field) and deep cell infiltration into adipose tissue were observed. These features led to the histopathological diagnosis of a malignant low-grade mesenchymal cell tumor. Immunohistochemical analysis revealed negative staining for α -SMA, S-100, and Bcl-2, but positive staining for Ki-67 (18%) and strong and diffuse staining for CD34. These findings were compatible with the diagnosis of DFSP. Only two cases of DFSP in the oral cavity, both involving the cheek mucosa, have been described so far, highlighting the rarity of the present case.

Keywords: Dermatofibrosarcoma; oral mucosal tumors

Introduction

Dermatofibrosarcoma protuberans (DFSP) is an uncommon and locally aggressive mesenchymal neoplasm characterized by high rates of local recurrence and a low risk of metastasis [1-3]. This tumor was described for the first time by Darier and Ferrard in 1924, and was called progressive and recurrent dermatofibroma [4]. One year later, in 1925, Hoffman observed that these lesions can manifest as large multilobular and protuberant nodules [5]. The official name dermatofibrosarcoma protuberans was thus introduced [6].

Skin DFSP mainly affects patients between 20 and 50 years of age, although it can occur at any age [7]. The tumor is found preferentially on the trunk, followed by the proximal portion of the limbs. The head and neck region is involved in only 10% to 15% of cases [1, 8, 9]. The clinical presentation of DFSP depends on the stage of the tumor. Generally, the tumor progresses slowly over a long period of time before entering the phase of rapid growth [3, 10]. In the early stages, skin DFSP appears as an asymptomatic, hardened plaque of purple, red-bluish, or brown color, which is firmly adhered to the skin but not to deeper tissues [11]. Diagnostic errors are common at this stage and the tumor may resemble keloids, epidermoid cysts, scars, or vascular malformations [12, 13].

Histopathologically, DFSP mainly consists of spindle-shaped cells in a fibrous stroma and variable amounts of collagen. The spindle-shaped (fibroblast-like) cells typically proliferate in interlacing fascicles, resulting in a storiform pattern as seen in various fibrous proliferations [3, 14]. Other features are a low mitotic activity and deep infiltration into subcutaneous adipose tissue [15, 16].

The definitive diagnosis of DFSP is generally established based on histopathological and immunohistochemical features. The immunohistochemical expression of CD34 is considered an important characteristic for the diagnosis of DFSP and positive expression is observed in 84% to 100% of cases [17].

According to the literature, the occurrence of DFSP in the oral cavity is rare. Therefore, the objective of this study is to report an uncommon case of DFSP in the buccal mucosa and to discuss the main diagnostic, histopathological and immunohistochemical criteria. The first case of DFSP in the oral mucosa was reported 16 years ago and this is the third case of oral DFSP.

Case synopsis

A 44-year-old woman consulted the Oral Diagnostics Service of the Federal University of Rio Grande do Norte, Natal, RN, Brazil, with a 5-month history of an asymptomatic lesion in the right buccal mucosa. Her medical history was non-contributory. Extraoral examination was unremarkable. The cervical lymph nodes were not palpable. The patient reported no history of local trauma. Intraoral examination revealed a yellow nodule in the submucosal plane of the right buccal mucosa, which was firm to palpation and measured 2.5 cm. The clinical diagnosis was lipoma.

An excisional biopsy was performed under local anesthesia (Figure 1).

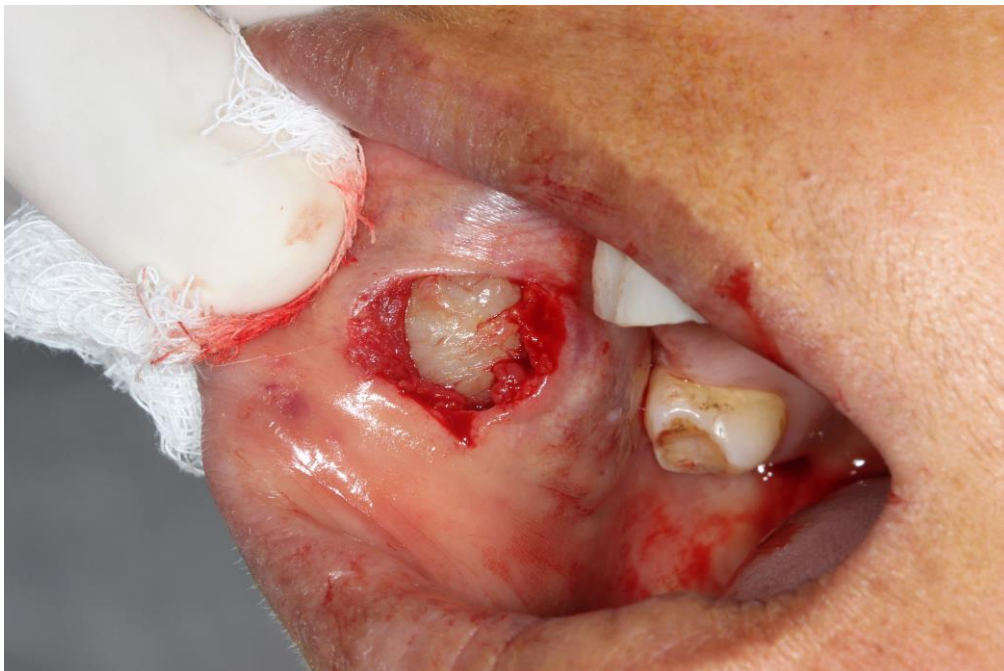


Figure 1. Transoperative image showing a nodular and yellowish lesion, firm on palpation (2.5 cm in size), in the submucosal plane of the right buccal mucosa.

Five soft tissue fragments were fixed in 10% formalin and sent for histopathological analysis. The specimens did not float in the fixative and had a white color, irregular shape and surface, and rubbery consistency. The specimens measured together 3.0 x 2.7 x 0.7 cm. Histopathological analysis revealed the proliferation of spindle-shaped mesenchymal cells arranged in interlacing fascicles amidst fibrous stroma. Low mitotic activity (2 mitoses per high power field) and deep cell infiltration into adipose tissue were observed (Figure 2).

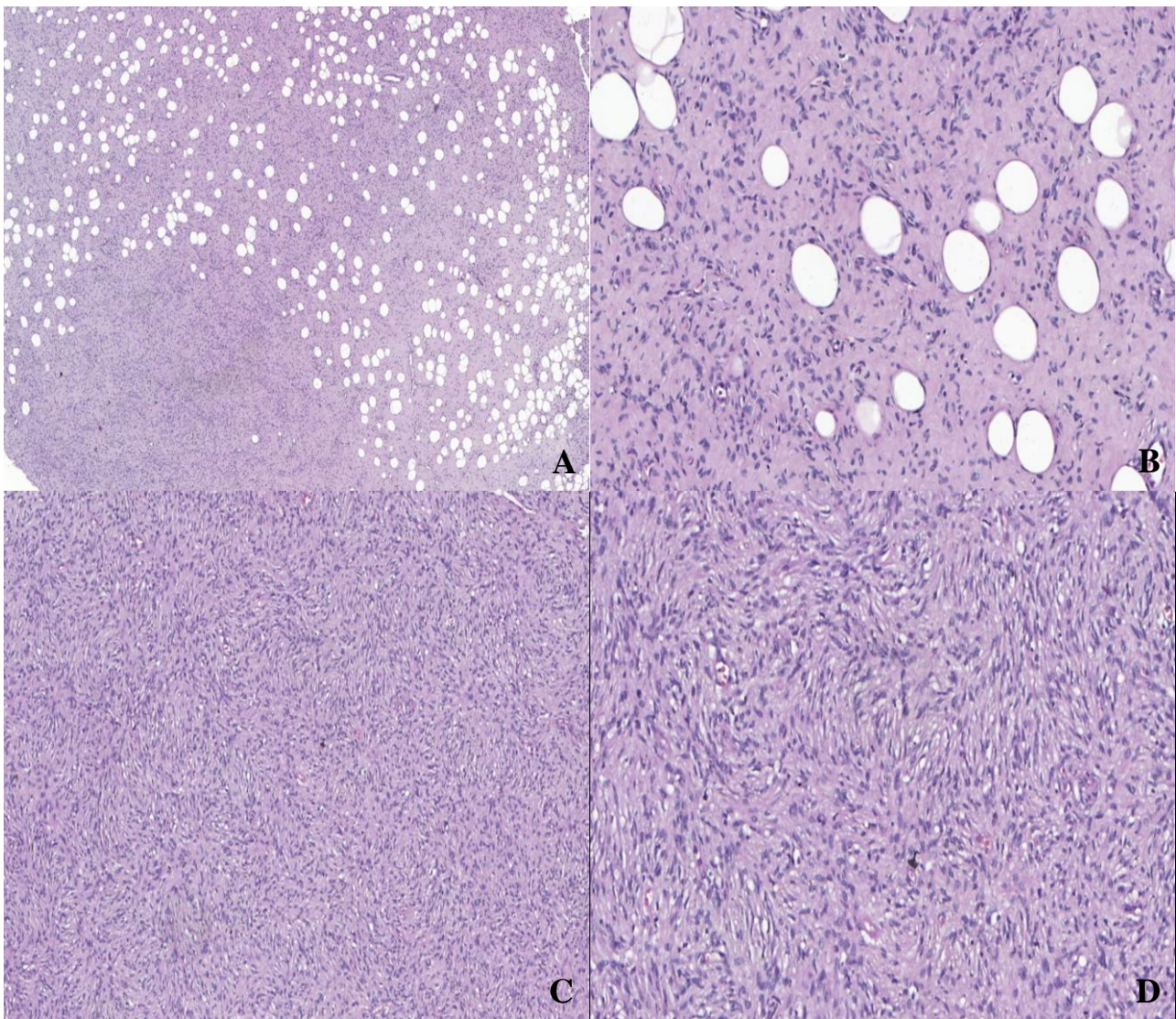


Figure 2. A) and B) Photomicrographs showing high cellularity consisting of spindle-shaped tumor cells infiltrating into adjacent adipose parenchyma. C) and D) Photomicrographs showing the proliferation of spindle-shaped mesenchymal cells arranged in interlacing fascicles amidst fibrous stroma and low mitotic activity (2 mitoses per field).

No areas of necrosis were identified. The tumor extended beyond the margins of the lesion. On the basis of these features, the histopathological diagnosis of a malignant low-grade mesenchymal cell tumor was proposed. The specimen was cut into 3- μ m thick sections for immunohistochemistry using anti- α -SMA, anti-S-100, anti-CD34, anti-Bcl-2, and anti-Ki-67 antibodies (Table 1).

Table 1. Summary of immunohistochemical protocols. Natal - RN, 2015.

Primary Antibody	Clone	Manufacturer	Dilution	Antigen retrieval	Incubation
Anti- α -SMA	1A4	Dako (Carpinteria, CA, USA)	1:300	Untreated	60min
Anti-S100A4	Polyclonal	Dako (Carpinteria, CA, USA)	1:400	Citrate, pH 6.0, Pascal	60min
Anti-CD34 class II	QBEnd-10	Dako (Carpinteria, CA, USA)	1:50	EDTA, pH 8.0, Pascal	60min
Anti-Ki67	Clone MIB-1	Dako (Carpinteria, CA, USA)	1:200	Citrate, pH 6.0, Pascal	60min
Anti-Bcl2	Clone 124	Dako (Carpinteria, CA, USA)	1:1000	Trilogy, Pascal, 3 minutes	60min

Immunohistochemical analysis and diagnosis

Immunohistochemical analysis was negative for α -SMA (Figure 3A), S-100 (Figure 3B), and Bcl-2 (Figure 3C). Immunohistochemical analysis was strong and diffuse staining for CD34 (Figures 3D), and the presence of Ki-67 (18%). These findings were compatible with the diagnosis of DFSP (Table 1).

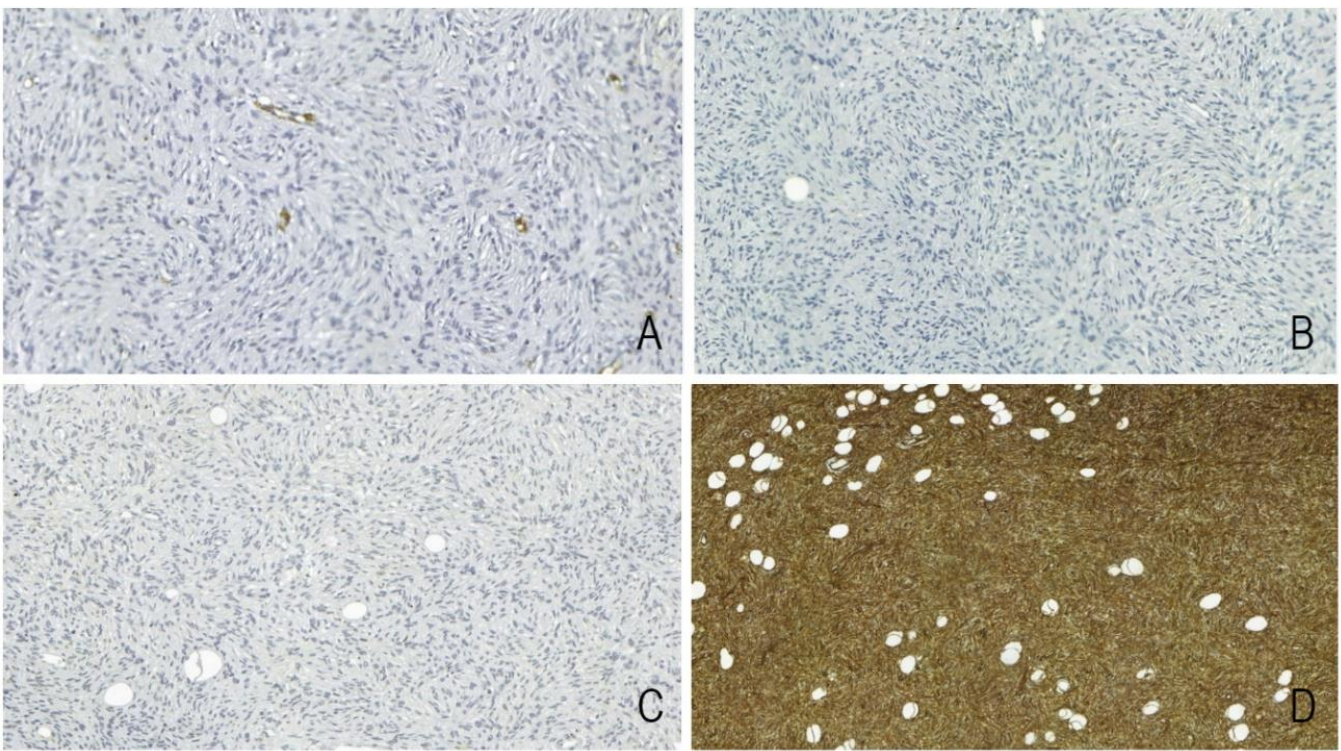


Figure 3. (A), (B) and (C) Immunohistochemical analysis showing negativity for α -SMA, S-100 and Bcl-2, respectively. (D) Immunohistochemical analysis for CD34 was strong and diffuse staining of the spindle-cell component (100%).

After diagnosis, the surgical margin was extended to avoid local recurrence. No postoperative radiotherapy was necessary. The patient was followed for 18 months without evidence of recurrence.

Discussion

DFSP is a rare skin tumor that accounts for about 6% of all intermediate-grade soft tissue sarcomas, with an estimated incidence of 0.8 cases per 1 million people per year [18]. This neoplasm was officially called dermatofibrosarcoma protuberans because of its multilobulated and/or protuberant clinical features [6]. However, in the present case, the lesion was located entirely within the submucosal tissue; we therefore decided to classify it as non-protuberans DFSP. Other cases of non-protuberans DFSP have been reported in the literature [19, 20-22].

Although cases of DFSP have been described in all races, an epidemiological study conducted in 2007 by Criscione and Weinstock showed that the incidence of DFSP among black individuals was approximately double the number of cases among whites [9]. Some studies have reported a discrete male preference [15, 23]. Our patient is a black woman.

Only two cases of DFSP involving the oral mucosa have been described [24, 25], a fact highlighting the rarity of the present case. Meehan *et al.* (1999) reported the first case of DFSP in the oral cavity, in which the tumor involved the buccal mucosa of a 44-year-old woman with a history of local trauma [24]. Nemenqani *et al.* in 2010, reported a case of DFSP also involving the cheek in a 64-year-old man [25]. In both cases, the characteristic histopathological findings and strong and diffuse staining for CD34 were important for the diagnosis of DFSP.

The occurrence of DFSP in the oral cavity provides evidence regarding its origin. Some authors proposed a fibroblastic origin because of its morphological similarity to malignant and benign fibrous histiocytoma [26, 27]. However, other studies support a perineural origin of DFSP [28, 29]. The present case suggests that the progenitor cell of DFSP is not only present in the skin, but also in submucosal tissue of the oral cavity.

The rarity of DFSP and its heterogeneous clinical presentations contribute to an incorrect preoperative diagnosis, which could lead to an inadequate biopsy [30], as in the present case. A history of trauma in the affected region is reported as a possible etiological factor of DFSP [3, 31]. There are also cases in which DFSP has been associated with surgical scars, burns, vaccine scars, and radiodermatitis [32-34]. None of these conditions was observed in the present patient.

The main histopathological feature of DFSP is the infiltration of neoplastic cells from the center of the tumor into surrounding tissues [1, 35]. Peripheral regions of the tumor invade subcutaneous tissue through finger-like projections. These tumor

extensions are poorly cellular and can resemble normal fibrous tissue, a fact impairing determination of the true extent of the tumor. This may explain recurrences even after excision with apparently wide margins [36].

The differential diagnoses of spindle cell lesions in the oral cavity include benign and malignant fibrohistiocytoma, desmoplastic melanoma, neurofibroma, myxoid liposarcoma, fibrosarcoma, and leiomyosarcoma [24, 37, 38]. Benign fibrohistiocytoma is characterized by the proliferation of spindle cells in a storiform pattern, epithelioid cells (histiocytic), and giant cells [39]. Malignant fibrohistiocytoma exhibits more cellular pleomorphism and mitotic figures when compared to DFSP. Furthermore, benign and malignant fibrohistiocytomas are negative for CD34 [39, 40], whereas DFSP is typically positive. Desmoplastic melanoma is characterized by spindle cells arranged in fascicles and cellular and nuclear atypia. In contrast to DFSP, this tumor is positive for S-100 [41]. Neurofibroma also shows strong positive staining for S-100 [42]. Generally, liposarcomas contain adipocytes of variable size with atypical nuclei and are positive for S-100 [43]. Despite the histological similarities, fibrosarcoma and leiomyosarcoma are negative for CD34 [44, 45].

According to Nemenqani *et al.* (2010), immunohistochemical analysis is very useful to establish the diagnosis of DFSP since it morphologically resembles several other spindle cell lesions that can affect the oral mucosa [25]. Within this context, immunoreactivity to CD34 was described in 1993 and this continues to be the main immunohistochemical marker for the diagnosis of DFSP, especially when associated with the absence of factor XIIIa staining [46, 47].

Another entity in the differential diagnosis of DFSP is solitary fibrous tumor (SFT). In addition to some histopathological similarities such as the storiform pattern and proliferation of spindle cells, both lesions exhibit strong positivity for CD34 [3, 14, 48]. However, SFT is characterized as a well-circumscribed lesion that can be partially or completely encapsulated in some cases [48], whereas DFSP is a poorly circumscribed lesion that displays typical infiltration of neoplastic cells into surrounding tissues [1, 31]. Furthermore, SFT is positive for Bcl-2 [48], a feature not found in DFSP, as observed in this case.

In recent years, new immunohistochemical markers have been studied for the diagnosis of DFSP, including stromelysin III, apolipoprotein D, nestin, and CD163. In summary, DFSP cells usually express CD34 antigen, apolipoprotein D, and nestin [49, 50], and are negative for factor XIII, stromelysin III, HMGA1, HMGA2, tenascin, D2-40, and CD163 [51, 52, 53]. In the present case, the combination of histopathological features with diffuse immunostaining for CD34 and negative staining for Bcl-2 was sufficient to establish the diagnosis of non-protuberans DFSP in the oral mucosa even though the tumor did not cause any visible swelling.

DFSP is considered a slow-growing tumor of low mitotic activity [25, 54]. These features were also observed in the present case, in which only two mitoses per field were found.

The development of metastases in DFSP is extremely rare (< 5%), but the risk of recurrence is high and is directly related to incomplete removal of the tumor [14, 54]. Therefore, the surgical margin was extended in an attempt to avoid recurrences since the tumor had infiltrated adipose tissue and striated muscle fibers.

Although molecular studies are not necessary for the routine pathological diagnosis of DFSP, identification of COL1A1/PDGFB (collagen type 1 alpha-1/platelet-derived growth factor beta) rearrangements is obligatory in cases in which the histopathology is inconclusive and immunohistochemical features are inaccurate (CD34 negative). Confirmation with this marker is also recommended before the beginning of treatment with imatinib mesylate in locally aggressive or metastatic cases [14].

Conclusion

In conclusion, DFSP is an uncommon malignant neoplasm of the skin, but can develop in the oral mucosa as a low-grade, slow-growing, and infiltrative tumor. Clinical and morphological similarities to other lesions may result in an inadequate diagnosis and treatment. This study reports a rare case of DFSP in the oral mucosa and describes the main morphological and immunohistochemical findings for establishment of the correct diagnosis.

References

1. Sanmartín O, Llombart B, López-Guerrero JA, Serra C, Requena C, Guillén C. Dermatofibrosarcoma Protuberans. *Actas Dermosifiliogr* 2007;98:77-87. [PMID: 17397592]
2. Rouhani P, Fletcher CD, Devesa SS, Toro JR. Cutaneous soft tissue sarcoma incidence patterns in the U.S.: an analysis of 12,114 cases. *Cancer* 2008;113(3):616-27. [PMID: 18618615]
3. Park TH, Seo SW, Kim JK, Chang CH. Reconstructive challenge of dermatofibrosarcoma protuberans in the female breast. *World J of Surg Oncol* 2011; 9:1. [PMID: 21214920]

4. Darier J, Ferrand M. Dermatofibromes progressifs et recidivants ou fibrosarcomes de la peau. *Ann Dermatol Syph* 1924;5:545-62.
5. Hoffman E. Über das knollentreibende fibrosarkom der haut (Dermatofibrosarkoma protuberans). *Dermat Ztschr* 1925;43:1-28.
6. Lim EK, Chia HL, Yu TJ, Chang HC. Suprapubic Dermatofibrosarcoma Protuberans: Case Report and Literature Review. *JTUA* 2008;19(4): 232-234.
7. Mehrany K, Swanson NA, Heinrich MC, Weenig RH, Lee KK, White CR Jr, Devere TS. Dermatofibrosarcoma Protuberans: A Partial Response to Imatinib Therapy. *Dermatol Surg* 2006;32(3): 456-459.
8. Fiore M, Miceli R, Mussi C, Lo Vullo S, Mariani L, Lozza L, Collini P, Olmi P, Casali PG, Gronchi A. Dermatofibrosarcoma protuberans treated at a single institution: a surgical disease with a high cure rate. *J Clin Oncol* 2005;23:7669-7675. [PMID: 16234529]
9. Criscione VD, Weinstock MA. Descriptive epidemiology of dermatofibrosarcoma protuberans in the United States, 1973 to 2002. *J Am Acad Dermatol* 2007; 56:968-973. [PMID: 17141362]
10. Billings SD, Folpe AL. Cutaneous and subcutaneous fibrohistiocytic tumors of intermediate malignance. *Am J Dermatopathol* 2004;26:151-50. [PMID: 15024197].
11. Wacker J, Khan-Durani B, Hartschuh W. Modified mohs micrographic surgery in the therapy of dermatofibrosarcoma protuberans: analysis of 22 patients. *Ann Surg Oncol* 2004; 11:438-444. [PMID: 15070606]
12. Tanaka A, Mitsuo H, Tada H, Kuwahara M, Iioka H, Niitsuma K. Dermatofibrosarcoma Protuberans arising from a burn scar of the axial. *Ann Plast Surg* 2004; 52(4):423-25. [PMID: 15084891]
13. Martin L, Piette F, Blanc P, Mortier L, Avril MF, Delaunay MM, Dréno B, Granel F, Mantoux F, Aubin F, Sassolas B, Adamski H, Dalac S, Pauwels C, Domp Martin A, Lok C, Estève E, Guillot B. Clinical variants of the preprotuberant stage of dermatofibrosarcoma protuberans. *Br J Dermatol* 2005;153: 932-936. [PMID: 16225602]
14. Llombart B, Serra-Guillén C, Monteagudo C, Guerrero JAL, Sanmartín O. Dermatofibrosarcoma protuberans: a comprehensive review and update on diagnosis and management. *Semin Diagn Pathol* 2013;30(1): 13-28. [PMID: 23327727]
15. Korkolis DP, Liapakis IE, Vassilopoulos PP. Dermatofibrosarcoma Protuberans: Clinicopathological Aspects of an Unusual Cutaneous Tumor. *Anticancer Res* 2007;27:1631-1634. [PMID: 17595787]
16. Lemm D, Mugge LO, Mentzel T, Hoffken K. Current treatment options in dermatofibrosarcoma protuberans. *J Cancer Res Clin Oncol* 2009; 135: 653-65. [PMID: 19205737]
17. Ruiz-Tovar J, Fernandez Guarino M, Reguero Callejas ME, Aguilera Velardo A, Arano Bermejo J, Cabanas Navarro L. Dermatofibrosarcoma protuberans: review of 20-years experience. *Clin Transl Oncol* 2006;8:606-610. [PMID: 16952850]
18. Lee SJ, Mahoney MC, Shaughnessy E. Dermatofibrosarcoma Protuberans of the Breast: Imaging Features and Review of the Literature. *AJR* 2009; 193 (July). [PMID: 19542385]
19. Diaz-Cascajo C, Weyers W, Rey-Lopez A, Borghi S. Deep dermatofibrosarcoma protuberans: a subcutaneous variant. *Histopathology*, 1998; 32: 552-5. [PMID: 9675595]
20. Ramakrishnan V, Shoher A, Ehrlich M, Powell S, Lucci AJ. Atypical dermatofibrosarcoma protuberans in the breast. *Breast J*, 2005; 11: 217-8. [PMID: 15871713]
21. Bulliard C, Murali R, Chang LY, Brennan ME, French J. Subcutaneous dermatofibrosarcoma protuberans in skin of the breast: may mimic a primary breast lesion. *Pathology*, 2007; 39: 446-8. [PMID: 17676490]
22. Shih, P, Chen C, Kuo T, Yang C, Huang Y, Yang C. Deep dermatofibrosarcoma protuberans: a pitfall in the ultrasonographic diagnosis of lipoma-like subcutaneous lesions. *Dermatol sinica*, 2010; 28: 32-35.
23. Stamatakos M, Fyllos A, Siafogianni A, Ntzeros K, Tasiopoulou G, Rozis M, Kontzoglou K. Dermatofibrosarcoma protuberans: a rare entity and review of the literature. *JBUON* 2014;19(1): 35. [PMID: 24659640]
24. Meehan SA, Napoli JA, Perry AE. Dermatofibrosarcoma protuberans of the oral cavity. *J Am Acad Dermatol* 1999;41(5) Pt 2: 863-6. [PMID: 10534672]
25. Nemenqani D, Yaqoob N, Khoja H, Al Qurashi A. Dermatofibrosarcoma protuberance of the oral cavity: Does it exist? *J Pak Med Assoc* 2010; 60 (March): 3. [PMID: 20225788]
26. Ozzello L, Hamels J. The histiocytic nature of Dermatofibrosarcoma Protuberans: Tissue culture and electron microscopic study. *Am J Clin Pathol* 1976;65:136. [PMID: 766604]
27. Guitierrez G, Ospina JE, De Baez NE. Dermatofibrosarcoma Protuberans. *Int J Dermatol* 1984;23:396. [PMID: 64800208]
28. Hashimoto K, Brownstein MH, Jakobiec FA. Dermatofibrosarcoma Protuberans. A tumor with perineural and endoneural cell features. *Arch Dermatol* 1974;110:874. [PMID: 44411109]
29. Weiss SW, Nickoloff BJ. CD34 is expressed by a distinctive cell population in peripheral nerve, nerve sheath tumors, and related lesions. *Am J Surg Pathol* 1993;17:1039. [PMID: 7690524]
30. Furtado JPR, Furtado CF, Alves JCB, Morais CS, Laporte GA. Dermatofibrosarcoma protuberans: experience and analysis of a clinical series. *Revista da AMRIGS* 2011;55 (1): 48-52.
31. Fleury Júnior LFF, Sanches Júnior JA. Primary cutaneous sarcomas. *An Bras Dermatol* 2006;81:207-21.
32. McLoughlin PM, Girach M, Wood GA. Dermatofibrosarcoma protuberans of the scalp. *Br J Oral Maxillofac Surg* 1992;30: 401-403. [PMID: 1450166]
33. Rabinowitz LG, Luchetti ME, Segura AD, Esterly NB. Acraly occurring dermatofibrosarcoma protuberans in children and adults. *J Dermatol Surg Oncol* 1994; 20: 655-659. [PMID: 7930009]

34. Kamar FG, Kairouz VF, Sabri NA. Dermatofibrosarcoma protuberans (DFSP) successfully treated with sorafenib: case report. *Clin Sarcoma Res* 2013;3:5. [PMID: 23557478]
35. Softah A. Recurrence of Dermatofibrosarcoma Protuberans: A Case Report and a Review of Literature. *Indian J Chest Dis Allied Sci* 2003;45:261-263. [PMID: 12962461]
36. Bague S, Folpe AL. Dermatofibrosarcoma protuberans presenting as a subcutaneous mass: a clinicopathological study of 15 cases with exclusive or near-exclusive subcutaneous involvement. *Am J Dermatopathol* 2008;30(4): 327-32. [PMID: 18645303]
37. Laskin WB. Dermatofibrosarcoma protuberans. *CA Cancer J Clin.* 1992; 42: 116-125. [PMID: 1540852]
38. His ED, Nickoloff BJ. Dermatofibroma and dermatofibrosarcoma protuberans: an immunohistochemical study reveals distinctive antigenic profiles. *J Dermatol Sci* 1996;11 (1): 1-9. [PMID: 8867761]
39. Chen H, Li P, Liu Z, Xu J, Hui X. Benign fibrous histiocytoma of the fronto-temporo-parietal region: a case report and review of the literature. *Int J Clin Exp Pathol*, 2015; 8 (11): 15356-15362. [PMID: 26823894]
40. Harsh KK, Kapoor A, Jakhar SL, Kumar HS. Giant cell variant of malignant fibrous histiocytoma of male breast: a rare case report. *J Cancer Res Ther*, 2015; 11 (3): 657. [PMID: 26458656]
41. Mărgăritescu I, Chiriță AD. Desmoplastic melanoma – challenges in the diagnosis and management of a rare cutaneous tumor. *Rom J Morphol Embryol*, 2014; 55 (3): 947–952. [PMID: 25329125]
42. Bharath TS, Krishna YR, Nalabolu GR, Pasupuleti S, Surapaneni S, Ganta SB. Neurofibroma of the Palate. *Case Rep Dent.*, 2014; 7 (April). [PMID: 24860683]
43. Kim YB, Leem DH, Baek JA, Ko SO. Atypical Lipomatous Tumor/ Well-Differentiated Liposarcoma of the Gingiva: A Case Report and Review of Literature. *J Oral Maxillofac Surg*, 2014; 72: 431-439. [PMID: 23992781]
44. Divyambika CV, Sathasivasubramanian S, Krithika CL, Malathi N, Prathiba D. Pediatric oral leiomyosarcoma: Rare case report. *J Cancer Res Ther.*, 2012; 8 (2): 282-5. [PMID: 22842376]
45. Reddy AVS, Prakash AR, Ram VS, Keerthana KL, Thorati RS. Intra Oral Fibrosarcoma with Various Histopathological Patterns: A Rare Case Report. *J Clin Diagn Res.*, 2015; 9 (7): 4-6. [PMID: 26393135]
46. Altman DA, Nickoloff BJ, Fivenson DP. Differential expression of factor XIIIa and CD34 in cutaneous mesenchymal tumors. *J Cutan Pathol* 1993; 20:154-158. [PMID: 7686570]
47. Kutzner H. Expression of the human progenitor cell antigen CD34 (HPCA-1) distinguishes dermatofibrosarcoma protuberans from fibrous histiocytoma in formalin-fixed, paraffin-embedded tissue. *J Am Acad Dermatol* 1993; 28:613-617. [PMID: 7681857]
48. O'Regan EM, Vanguri V, Allen CM, Eversole LR, Wright JM, Woo SB. Solitary Fibrous Tumor of the Oral Cavity: Clinicopathologic and Immunohistochemical Study of 21 Cases. *Head Neck Pathol.*, 2009; 3 (2): 106-15. [PMID: 19644541]
49. West RB, Harvell J, Linn SC, Liu CL, Prapong W, Hernandez-Boussard T, Montgomery K, Nielsen TO, Rubin BP, Patel R, Goldblum JR, Brown PO, Van de Rijn M. Apo D in soft tissue tumors. A novel marker for dermatofibrosarcoma protuberans. *Am J Surg Pathol* 2004;28(8):1063-1069. [PMID: 15252314]
50. Mori T, Misago N, Yamamoto O, Toda S, Narisawa Y. Expression of nestin in dermatofibrosarcoma protuberans in comparison to dermatofibroma. *J Dermatol* 2008; 7:419-25. [PMID: 18705829]
51. Sachdev R, Sundram U. Expression of CD163 in dermatofibroma, cellular fibrous histiocytoma, and dermatofibrosarcoma protuberans: comparison with CD68, CD34, and Factor XIIIa. *J Cutan Pathol* 2006;33 (5): 353-60. [PMID: 16640542]
52. Kim HJ, Lee JY, Kim SH, Seo YJ, Lee JH, Park JK, Kim MH, Cinn YW, Cho KH, Yoon TY. Stromelysin-3 expression in the differential diagnosis of dermatofibroma and dermatofibrosarcoma protuberans: comparison with factor XIIIa and CD34. *Br J Dermatol* 2007; 157:319-24. [PMID: 17596171]
53. Bandarchi B, Ma L, Marginean C, Hafezi S, Zubovits J, Rasty G. D2-40, a novel immunohistochemical marker in differentiating dermatofibroma from dermatofibrosarcoma protuberans. *Mod Pathol* 2010;23: 434–438. [PMID: 20062007]
54. Galimbert G, Montañ AP, Kowalczyk A, Ferrario D, Galimberti R. Outcomes in 11 patients with dermatofibrosarcoma protuberans treated with Mohs micrographic surgery. *Int J Dermatol.* 2012;51: 89-93. [PMID: 22182384]