

Case report

Treatment of metastatic cutaneous Crohn disease with certolizumab

Maija Kiuru MD PhD¹, Brendan Camp MD², Katayun Adhami MD³, Vinita Jacob MD⁴, Cynthia Magro MD², Horatio Wildman MD³

Dermatology Online Journal 21 (11): 4

¹Department of Dermatology, University of California Davis, Sacramento, California

²Department of Pathology, ³Dermatology, and ⁴Gastroenterology, Weill Cornell Medical College, New York, New York

Correspondence:

Maija Kiuru MD, PhD
Email: mkiuru@ucdavis.edu
Tel: 916-734-0591
Fax: 916-734-6793
Department of Dermatology, University of California Davis
3301 C Street, Suite 1400, Sacramento, California 95816

Abstract

Metastatic Crohn disease is a rare cutaneous manifestation of Crohn disease characterized by granulomatous lesions discontinuous with the diseased areas of the gastrointestinal tract. We report a case of a 32-year-old woman with history of Crohn disease who was admitted for treatment of cellulitis after presenting with a tender erythematous plaque of the left calf. Microbiological tests including tissue cultures were negative. A skin biopsy revealed granulomatous dermatitis consistent with metastatic cutaneous Crohn disease. Owing to concomitant perianal fistulas and abscesses and prior infusion reaction to infliximab, the patient was treated with certolizumab, a pegylated tumor necrosis factor (TNF) inhibitor combined with methotrexate resulting in complete resolution of the skin lesion. This case emphasizes the importance of recognizing this rare skin manifestation of Crohn disease and adds certolizumab as one of TNF inhibitors useful in the treatment of metastatic cutaneous Crohn disease.

Keywords: Metastatic cutaneous Crohn disease, certolizumab

Introduction

Metastatic cutaneous Crohn disease is a rare skin manifestation of Crohn's disease characterized by granulomatous inflammation discontinuous with the gastrointestinal tract [1,2]. Most commonly, it presents as erythematous plaques or nodules in the intertriginous areas, abdomen, and lower extremities, and can be mistaken both clinically and histologically for sarcoidosis or infection. The first-line therapy includes lesional or systemic corticosteroids and controlling the underlying gastrointestinal disease [2]. Herein, we describe a case of metastatic cutaneous Crohn disease successfully treated with certolizumab (certolizumab pegol), a pegylated tumor necrosis factor (TNF) inhibitor, and methotrexate.

Case synopsis

A 32-year-old female with history of Crohn disease presented to the emergency department with a two-week history of a tender plaque of the left calf that had not responded to sulfamethoxazole/trimethoprim. She was admitted for cellulitis and started on intravenous vancomycin and piperacillin/tazobactam. Owing to lack of improvement after three days, the dermatology department was consulted. The patient was taking methotrexate for Crohn disease but was suffering from perianal fistulas and abscesses. She also had a distant history of erythema nodosum.

On physical examination, she was afebrile and had a tender indurated erythematous plaque with scale on the left calf (Figure 1). White blood cell count with differential was within normal limits. Sonogram of the left calf revealed mild soft tissue edema. Two skin biopsies were obtained, one for tissue culture and another for hematoxylin-eosin staining (Figure 2). Tissue culture for bacteria, fungi, and atypical mycobacteria was negative.

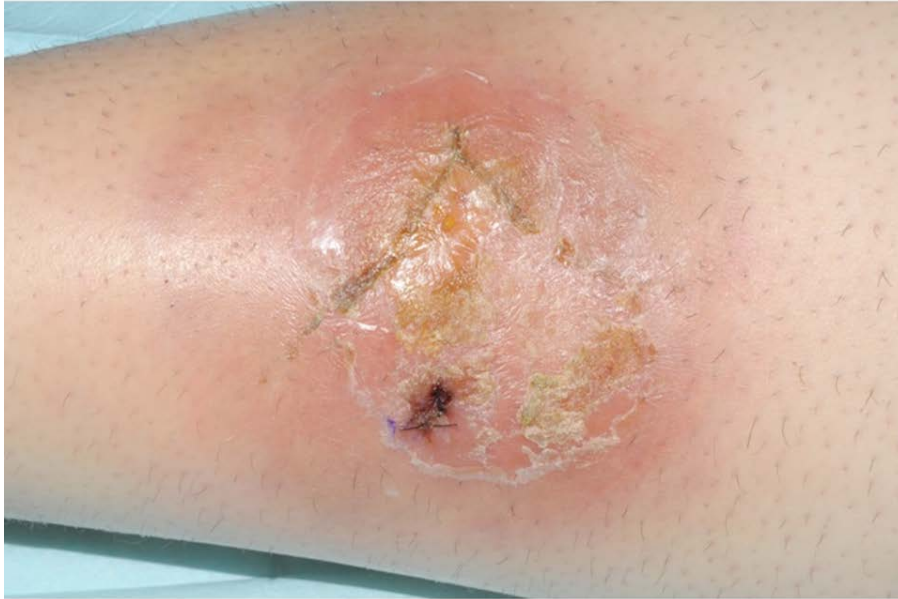

Figure 1. An erythematous plaque of the left calf with central scale and crust

The biopsy showed an intense inflammatory cell infiltrate throughout the dermis, which was more prominent in the deeper aspect of the biopsy (Figure 2a). The infiltrate was comprised of lymphocytes, neutrophils, and histiocytes (Figure 2b). The histiocytes were closely aggregated to produce granulomas. There were scattered Langhans giant cells. In addition, there was a supervening granulomatous arteritis with concentric luminal and mural fibrin deposition with an infiltrate of histiocytes within the vessel wall. At the very base of the biopsy there was a very prominent neutrophilia with nuclear debris. Acid fast, gram, and periodic acid-shiff stains were negative.

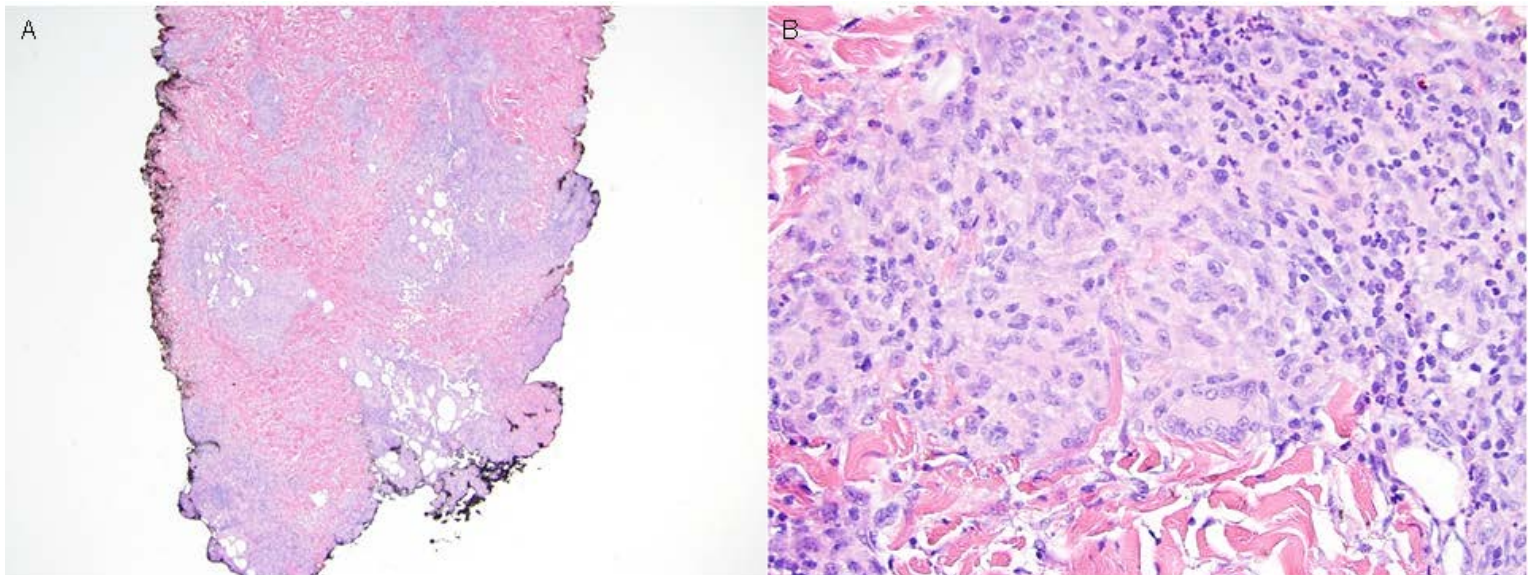


Figure 2. Histopathology of the plaque showing a nodular infiltrate in the dermis (2a) with granulomas (2b) Neutrophils are also present (2b). Hematoxylin and eosin stain, 20x (2a) and 400x (2b).

In addition to the cutaneous disease, our patient suffered from perianal abscesses and fistulas. The patient had a history of a prior infusion reaction with infliximab and had failed adalimumab combined with methotrexate in the past, and was therefore treated with the pegylated TNF inhibitor, certolizumab, combined with methotrexate. Two weeks after the first infusion, the plaque on the left calf showed marked improvement, with complete resolution at six weeks (Figure 3). Her perianal abscesses resolved and her disease remained controlled in follow up of three years.

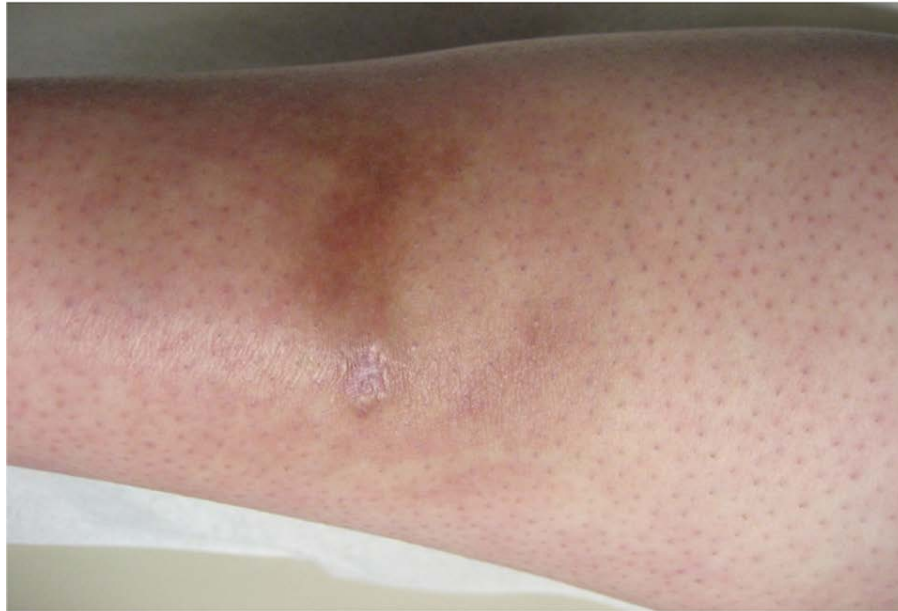

Figure 3. Resolution of the plaque after treatment with certolizumab and methotrexate

Discussion

Crohn disease is characterized by segmental granulomatous inflammation of the intestinal tract. Mucosal and skin findings occur in 18-44 % of patients [1, 2], and include distant metastatic cutaneous Crohn disease, contiguous perianal Crohn disease, oral Crohn disease, reactive dermatologic diseases (including erythema nodosum and pyoderma gangrenosum), and nutritional skin changes [3].

Metastatic cutaneous Crohn disease is defined by the presence of cutaneous granulomatous lesions well removed from the affected of the gastrointestinal tract. Fewer than 100 cases of metastatic cutaneous Crohn have been reported in the literature [4]. Sites most commonly involved are the intertriginous and flexural regions, abdomen, and lower extremities [5, 6]. Involvement of the vulva, penis, trunk, upper extremities, and face [5, 6] (in order of decreasing frequency) has also been reported. Non-genital disease presents with erythematous to purple plaques or nodules, often followed by ulceration with undermined edges, draining sinuses and fistulae, ultimately leading to scar formation. Median age of onset is 34.5 years, with some reports showing a predilection toward females [1, 2].

Clinically, the differential diagnosis of metastatic cutaneous Crohn disease includes other granulomatous disorders such as cutaneous sarcoidosis, mycobacterial infections, deep fungal infections, actinomycosis, cellulitis, and foreign body reactions.

Microscopic examination of metastatic cutaneous Crohn disease shows nodular non-caseating granulomas, similar to those seen in the bowel and in sarcoidosis, located primarily in the superficial and deep dermis, sometimes extending into the subcutaneous fat [4]. Scattered multinucleated Langhans-type giant cells and a sparse perivascular lymphohistiocytic infiltrate are present. There can be associated vascular injury, typically with a prominent extravascular neutrophilic and/or histiocytic dermal infiltrate [7]. The distinction from cutaneous sarcoidosis may be aided by the presence of ulcerated epidermis, lymphocytic and eosinophilic infiltrate, vasculitis, and massive edema of the dermis, which are not characteristic of sarcoidosis [8].

Metastatic cutaneous Crohn disease tends to have a chronic course. There is no consistent correlation between the appearance of skin lesions and intestinal Crohn disease activity [5, 6]. Cutaneous lesions have been reported to respond to treatment aimed at the underlying intestinal disease. Either topical or systemic corticosteroids can be considered as a first-line therapy for metastatic Crohn disease [2]. Varying success has been reported with oral metronidazole, sulfasalazine, azathioprine, and 6-mercaptopurine.

Finally, TNF inhibitors provide an important therapeutic option especially for patients that fail other traditional therapies [9, 10, 11].

Certolizumab (certolizumab pegol) is a humanized antigen-binding (Fab) fragment of a monoclonal TNF antibody that has been conjugated to polyethylene glycol [12]. Pegylation improves drug pharmacokinetics and bioavailability [13]. It increases the half-life of certolizumab and the penetration of the drug in inflamed tissue [12]. Certolizumab differs from the other TNF inhibitors, such as adalimumab, by lacking an Fc region, which potentially minimizes complement-dependent cytotoxicity or antibody dependent cell-mediated cytotoxicity [12]. Certolizumab has been successfully used and is approved for Crohn disease, psoriatic arthritis, rheumatoid arthritis, and ankylosing spondylitis [14]. Although rare reports exist of using certolizumab for treatment of refractory pyoderma gangrenosum in Crohn disease [15,16], the treatment of metastatic cutaneous Crohn disease with certolizumab is without precedent.

In summary, metastatic Crohn disease is a rare entity that should be included in the diagnostic considerations for a persistent plaque or nodule in a patient with history of Crohn disease. Diagnosis can be confirmed by a skin biopsy showing sarcoidal granulomatous dermatitis, after exclusion of other causes for this histopathological pattern including sarcoidosis and infection. Treatment targets the underlying intestinal disease and is individualized ranging from corticosteroids to TNF inhibitors. Our case of metastatic cutaneous Crohn disease successfully treated with certolizumab and methotrexate underscores the importance of recognizing this rare dermatologic manifestation of Crohn disease and presents certolizumab as a new alternative for the treatment of metastatic cutaneous Crohn disease.

References

1. Lester LU, Rapini RP. Dermatologic manifestations of colonic disorders. *Curr Opin Gastroenterol*. 2009 Jan;25(1):66-73. [PMID 19119511]
2. Kurtzman DJ, Jones T, Lian F, Peng LS. Metastatic Crohn's disease: a review and approach to therapy. *J Am Acad Dermatol*. 2014 Oct;71(4):804-13. PMID: 24888520.
3. Burgdorf W. Cutaneous manifestations of Crohn's disease. *J Am Acad Dermatol*. 1981 Dec;5(6):689-695. [PMID 6459345]
4. Alan Siroy, Jay Wasman. Metastatic Crohn Disease: A Rare Cutaneous Entity. *Arch of Pathol Lab Med*. 2012 Mar;136(3):329-332. [PMID 2372910]
5. Albuquerque A, Magro F, Rodrigues S, Lopes J, Lopes S, Dias JM, Carneiro F, Macedo G. Metastatic cutaneous Crohn's disease of the face: a case report and review of the literature. *Eur J Gastroenterol Hepatol*. 2011 Oct;23(10):954-956. [PMID 21900789]
6. Ogram AE, Sobanko JF, Nigra TP. Metastatic cutaneous Crohn disease of the face: a case report and review of the literature. *Cutis*. 2010 Jan;85(1):25-27. [PMID 20184208]
7. Crowson AN, Nuovo GJ, Mihm MC Jr, Magro C. Cutaneous manifestations of Crohn's disease, its spectrum, and its pathogenesis: intracellular consensus bacterial 16S rRNA is associated with the gastrointestinal but not the cutaneous manifestations of Crohn's disease. *Hum Pathol*. 2003 Nov;34(11):1185-1192. [PMID 14652821]
8. Emanuel PO1, Phelps RG. Metastatic Crohn's disease: a histopathologic study of 12 cases. *J Cutan Pathol*. 2008 May;35(5):457-61. [PMID 18261113]
9. Rispo A, Scarpa R, DiGirolamo E, et al. Infliximab in the treatment of extra-intestinal manifestations of Crohn's disease. *Scand J Rheumatol*. 2005 Sep-Oct;34(5):387-391. [PMID 16234187]
10. Cury DB, Moss AC, Elias G, Nakao A. Adalimumab for cutaneous metastatic Crohn's disease. *Inflamm Bowel Dis*. 2010 May;16(5):723-724. [PMID 19728388]
11. Miller FA, Jones CR, Clarke LE, Lin Z, Adams DR, Koltun WA. Successful use of adalimumab in treating cutaneous metastatic Crohn's disease: report of a case. *Inflamm Bowel Dis*. 2009 Nov;15(11):1611-1612. [PMID 19090557]
12. Goel N, Stephens S. Certolizumab pegol. *MAbs*. 2010 Mar-Apr;2(2):137-47. [PMID 20190560]
13. Harris JM, Chess RB. Effect of pegylation on pharmaceuticals. *Nat Rev Drug Discov*. 2003 Mar;2(3):214-21. [PMID 12612647]
14. Schreiber S, Khaliq-Kareemi M, Lawrance IC, Thomsen OØ, Hanauer SB, McColm J, Bloomfield R, Sandborn WJ; PRECISE 2 Study Investigators. Maintenance therapy with certolizumab pegol for Crohn's disease. *N Engl J Med*. 2007 Jul 19;357(3):239-50. [PMID 17634459]
15. Cinotti E, Labeille B, Perrot JL, Pallot-Prades B, Cambazard F. Certolizumab for the treatment of refractory disseminated pyoderma gangrenosum associated with rheumatoid arthritis. *Clin Exp Dermatol*. 2014 Aug;39(6):750-1. [PMID 24984791]
16. Hurabielle C1, Schneider P, Baudry C, Bagot M, Allez M, Viguier M. Certolizumab pegol - A new therapeutic option for refractory disseminated pyoderma gangrenosum associated with Crohn's disease. *J Dermatolog Treat*. 2015 Apr;24:1-3. [PMID 25909366]