

Case Report

Increasing recognition of dermatomyositis with subcutaneous edema – is this a poorer prognostic marker?

Jenny Tu MBBS¹, Andrew McLean-Tooke MBChB MD FRCP FRCPATH FRACP FRCPA¹, Reimar Junckerstorff MBBS FRCPA²

Dermatology Online Journal 20 (1): 3

¹Immunology Department, Sir Charles Gairdner Hospital

²Section of Neuropathology, PathWest Laboratory Medicine WA Royal Perth Hospital

Correspondence:

Jenny Tu, MBBS
Immunology Department, Sir Charles Gairdner Hospital
Hospital Avenue, Nedlands, WA, 6009
Telephone number – 618 93463333
Email – jenny.tu@health.wa.gov.au

Abstract

Subcutaneous edema as a presenting feature of dermatomyositis has infrequently been described and is thought to signify a more aggressive disease course. We report a case involving a 38-year-old man who presented with significant subcutaneous edema involving his neck and upper body; he later developed clinical features and biopsy results consistent with dermatomyositis. Only sixteen previous cases of dermatomyositis with subcutaneous edema involving adults have been published in the literature and we aim to review disease progression, prognosis, and optimal treatment of the condition.

Key Words: Dermatomyositis, subcutaneous edema, muscle weakness, myositis

Introduction

There have been rare case reports of patients with DM presenting with subcutaneous edema, which heralds the development of more typical skin and muscle symptoms. We report the occurrence of subcutaneous edema, generalized skin eruption, and eventual diagnosis of DM in a 38-year-old man, and discuss disease progression, prognosis, and literature regarding this atypical presentation.

Case synopsis

A previously healthy 38-year-old man presented to our hospital with increasing periorbital, facial, upper limb, and trunk edema, a generalized skin eruption over the chest and trunk, myalgia, and fatigue. He had used betamethasone valerate cream, ibuprofen 400mg, and oral antibiotics (amoxicillin trihydrate and potassium clavulanate and doxycycline) without clinical improvement. He worked in the abattoir industry skinning and gutting animals. No sick contacts were reported at work. There was no significant family history or relevant travel history.

On examination, he had marked edema of the face, neck, and upper limbs. There was a widespread macular erythematous eruption with an area of blistering over his anterior chest. Neurological examination demonstrated slightly reduced proximal strength (4+/5) compared to distal power (5/5). No focal neurological signs were elicited. Cardiovascular, respiratory, and abdominal examinations were unremarkable.

Baseline hematological and biochemical investigations revealed a neutrophilia ($24.11 \times 10^9/L$: normal $2.0-7.5 \times 10^9/L$), thrombocytopenia ($105 \times 10^9/L$: normal $150-400 \times 10^9/L$), low sodium (127mmol/L , normal $134-136\text{mmol/L}$), elevated ALT of 473 U/L (normal $<40\text{ U/L}$), and GGT of 196 U/L (normal $<60\text{ U/L}$). Inflammatory markers were elevated with CRP at 43 mg/L (normal $<5\text{mg/L}$) and ESR 49 (normal $1-15\text{ mm/hr}$). Lactate dehydrogenase (LDH) levels were increased at 2290 U/L (normal $125-250\text{U/L}$). The patient's creatinine kinase (CK) level was significantly elevated, peaking at $61,000\text{ U/L}$ (normal $30-190\text{ U/L}$) during the first week of hospitalization.

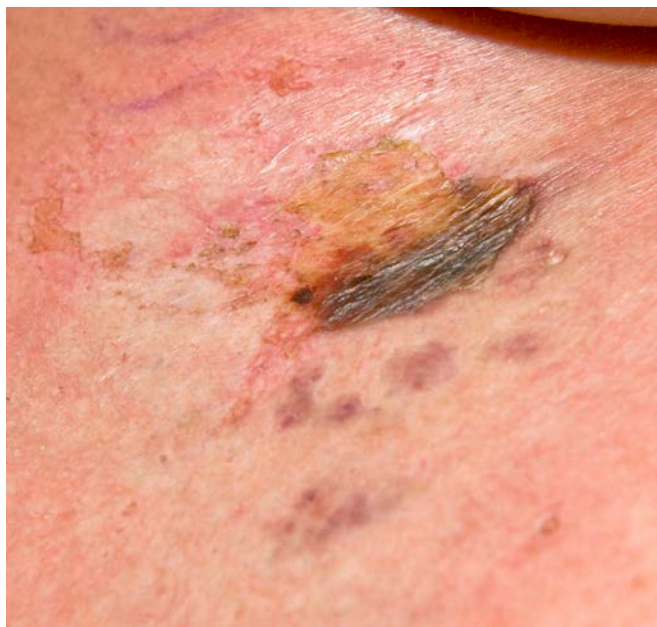

Figure 1. Skin eruption on central upper chest demonstrating a resolving area of blistering

His ANA level was positive at 10 IU/mL with a speckled pattern; ENA, ANCA, ds-DNA, complements (C3, C4), Rheumatoid factor, and anti-citrullinated protein antibodies were normal. Further testing for myositis specific antibodies (including Jo-1, Ro52, PL-12, PL-7, PM-Scl, Ku, Mi-2, anti-SRP) were all negative. A full septic screen and extensive viral serology were all negative. An initial skin biopsy of the right chest wall showed non specific ulceration and dermal necrosis.

The patient underwent an abdominal ultrasound, which was unremarkable. CT of the abdomen demonstrated non-specific edema and swelling in his anterior abdominal wall muscles and subcutaneous tissues. He was commenced on intravenous benzylpenicillin and vancomycin. However, he continued to deteriorate. Clinical immunology review was undertaken and given his marked proximal myopathy, elevated CK, skin changes including Gottron papules, rash over the anterior chest, neck, shoulders, back (Shawl sign), and lateral thighs (Holsters sign), a diagnosis of dermatomyositis was made. He was started on prednisolone 1mg / kg. Owing to a combination of respiratory muscle weakness and left lower lobe collapse and consolidation, the patient developed respiratory failure requiring intubation and ventilation. Marked edema and swelling of his airways was noted on laryngoscopy.

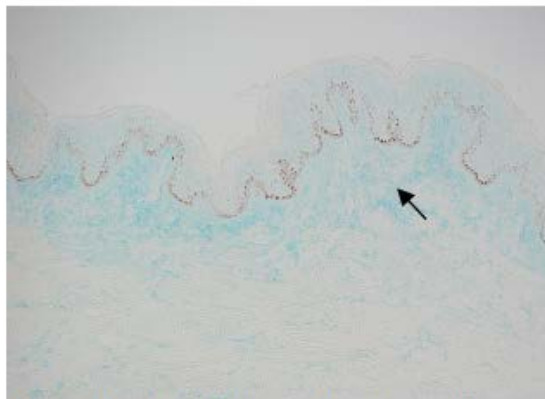


Figure 2A. An Alcian blue stain shows interstitial mucin deposition in the superficial dermis.

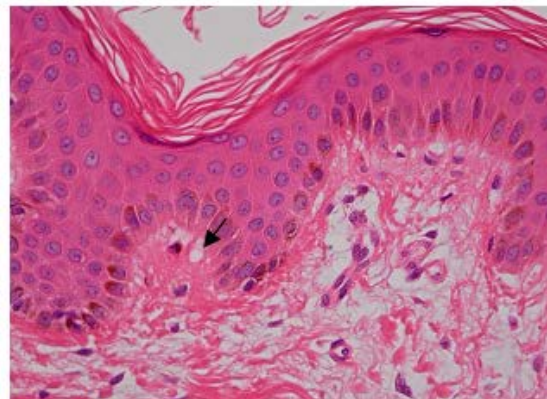


Figure 2B. Focal basal vacuolar change at the dermo-epidermal junction.

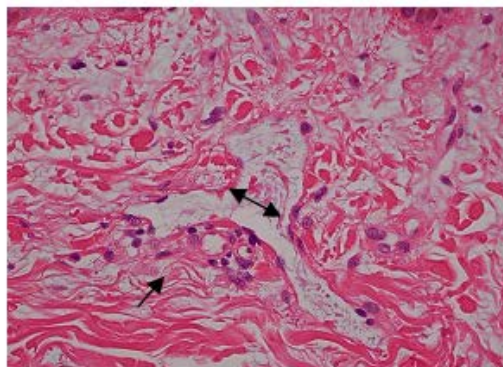


Figure 2C. A high power view of superficial dermis showing telangiectasia (double headed arrow) and mucinosis (arrow).

Intravenous methylprednisolone 100mg QID was commenced.

Skin biopsy from his left flank demonstrated prominent dermal mucinosis with minor epidermal changes and a mixed perivascular inflammation, consistent with dermatomyositis (Figure 2). Muscle biopsy from his right thigh demonstrated several necrotic fibers, mostly at the periphery of fascicles, and early myotube formation. Immunohistological staining showed MHC-I over-expression but no deposition of membrane attack complex. Electron microscopy showed occasional atrophic fibers and thickening of the capillary basal lamina. The histological features were consistent with an immune-mediated necrotizing myopathy (Figure 3). Comprehensive cancer screening including tumor markers, CT chest and abdomen, ENT review, and upper and lower gastrointestinal endoscopy were all normal.

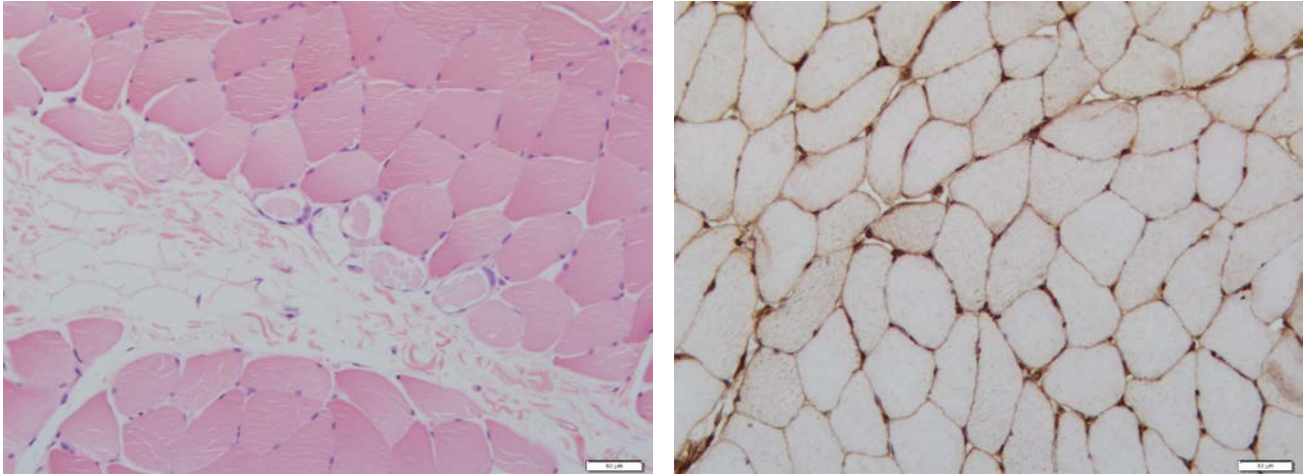


Figure 3A. Perifascicular muscle fiber necrosis with early myotube formation

Figure 3B. Immunihistochemical staining demonstrating MHC class I over-expression

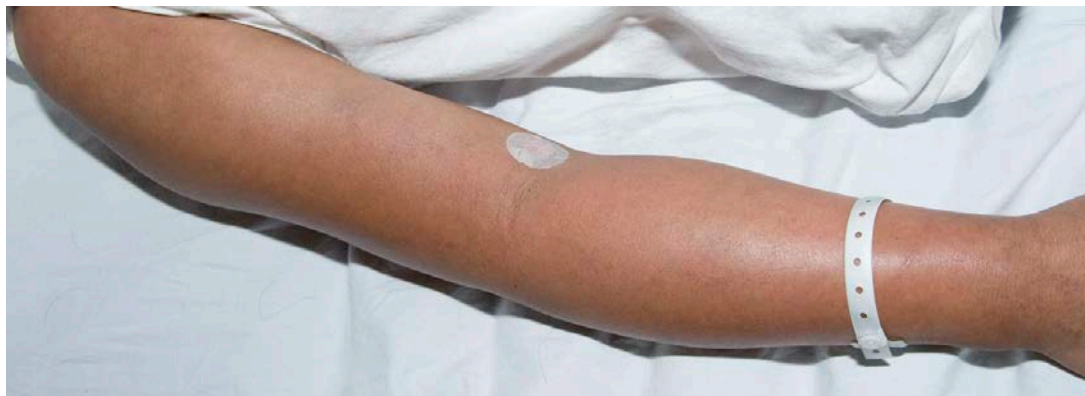

Figure 4. Localized upper limb edema predominantly in the forearms and deltoid areas.

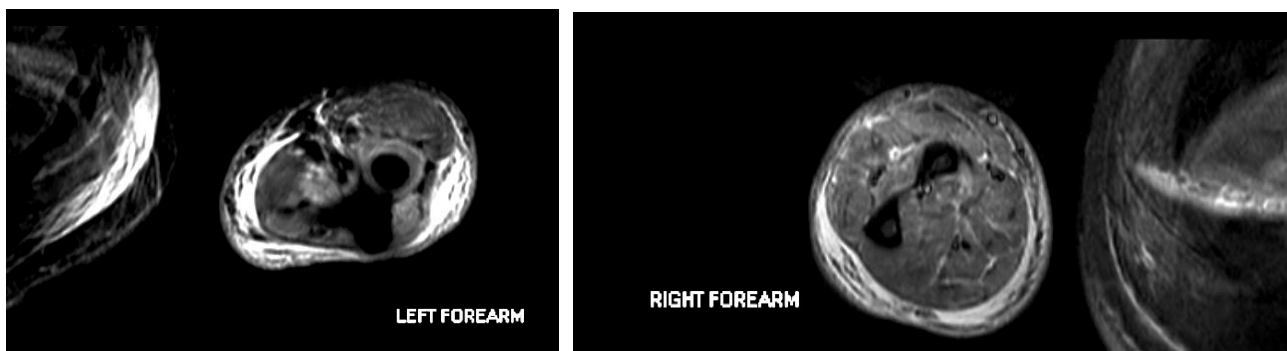

Figure 5. MRI scan of the forearms demonstrating generalized high signal within the muscle consistent with myositis and a moderate amount of edema within the subcutaneous fat.

Over the next few weeks, the patient experienced multiple episodes of respiratory distress, requiring airway support and eventual emergency tracheostomy insertion. Owing to ongoing respiratory muscle weakness and decompensation despite high dose steroids, two courses of high dose intravenous immunoglobulin (IVIg) (2mg/kg) were given four weeks apart.

After five weeks he was transferred to the Respiratory Unit. He was commenced on methotrexate 10mg/week; the dose was increased to 15mg/week. Unfortunately, he experienced a flare of disease seven weeks into this admission with rising CK, prominent localized proximal upper limb edema (Figure 4), and decrease in muscle strength. MRI of the forearms

demonstrated features of myositis and moderate edema within the subcutaneous fat (Figure 5). His methotrexate and corticosteroids were continued with gradual improvement of his edema and strength. After nine weeks of inpatient care he was transferred across to a rehabilitation unit.

Table 1 – Reported Cases of Dermatomyositis (DM), Polymyositis (PM) & Subcutaneous edema

Case	Year of Publication	Author	Case Details	Diagnosis (DM vs PM)	Treatment	Outcome
1)	1982	Venables GS, et al	73, male, edema in upper and lower limbs	PM	Prednisolone, Azathioprine	Death
2)	1982	Venables GS, et al	32, male, edema in upper and lower limbs	PM	Prednisolone	Recovery
3)	1982	Venables GS, et al	52, male, edema in upper and lower limbs	PM	Prednisolone, Azathioprine	Death
4)	1985	Lyon-Caen O, et al	65, male, edema in upper limbs, shoulders	PM	Observation	Recovery
5)	1993	Andonopoulos AP, et al	56, male, edema in upper limbs, lower limbs and trunk	PM	Prednisolone	Recovery
6)	1988	Nitshe A. et al	62, female, edema in upper limbs, abdomen, trunk	DM	Prednisolone	Recovery
7)	2000	Smyth AE, Bell AL.	27, female, edema in forearms	DM	Prednisolone, Azathioprine	Recovery
8)	2001	Gorelik O, et al	31, male, edema in upper limbs, trunk and pelvis / femoral region (on MRI)	DM	Hydrocortisone, intravenous immunoglobulin, prednisolone	Recovery
9)	2001	Gorelik O, et al	63, male, edema in left forearm	DM	Observation	Recovery
10)	2003	Thurairajah P, et al	54, male, edema in lower limb	PM	Methylprednisolone, Methotrexate	Recovery
11)	2003	Mroue KH, et al	78, female, edema in upper limbs	DM	Prednisolone, Methotrexate	Recovery before death from PE
12)	2006	Werner de Castro GR, et al	40, male, edema in upper and lower limbs and trunk	DM	Prednisolone, intravenous immunoglobulin	Death
13)	2007	Ito et al	78, female, edema in upper and lower limbs	DM	Prednisolone	Recovery
14)	2007	Dunkley L, Jawad A.	29, female, edema in upper limbs, face.	DM	Prednisolone, Methylprednisolone, Cyclophosphamide	Death
15)	2007	Kapaskelis P, Falagas M.	55, female, edema in face	DM	Prednisolone	Recovery
16)	2008	Lee et al	48, female, edema in upper, lower limbs, face, trunk	DM	Methylprednisolone, methotrexate, intravenous immunoglobulin	Recovery
17)	2011	Haroon M et al	61, female, edema in face, upper limbs	DM	Prednisolone, azathioprine, mycophenolate mofetil, intravenous immunoglobulin	Recovery
18)	2011	Chai et al	62, male, generalised edema	DM	Prednisolone, methotrexate	Recovery
19)		Chai et al	23, female, limb edema	DM	Prednisolone, methotrexate, intravenous immunoglobulin	Recovery
20)		Chai et al	38, female, generalised	DM	Prednisolone,	Recovery

			edema		methotrexate, intravenous immunoglobulin	
21)		Chai et al	38, male, upper limb edema	DM	Methylprednisolone, intravenous immunoglobulin, methotrexate	Recovery
22)	2012	Jung et al	52, female, generalised edema	DM	Methylprednisolone, prednisolone, intravenous immunoglobulin, azathioprine, cyclosporine	Recovery
23)	2012	Current case	38, male, edema in face, upper trunk, upper limbs	DM	Prednisolone, hydrocortisone, intravenous immunoglobulin, methotrexate	Recovery

Discussion

Dermatomyositis is a widespread, systemic inflammatory condition associated with pathognomonic skin changes. The widely accepted Bohan and Peter criteria for diagnosis relate to changes including symmetric proximal muscle weakness, typical skin eruption, increase in serum muscle enzymes, and characteristic changes in electromyography and muscle biopsy [1]. Generalized subcutaneous edema as a presenting feature of dermatomyositis has infrequently been described—only sixteen cases have been reported in the literature. We review these cases and hypothesize that this subset of patients has a poorer prognosis.

Nitsche et al first published a case of widespread subcutaneous edema as part of the dermatomyositis syndrome in 1988 [2]. However, the occurrence of this symptom in patients with the condition is rare and when Bohan and Peter published their clinical criteria for diagnosis, this was not included in the diagnostic list [1]. A comprehensive literature search using Medline and Pubmed over the past 30 years identified only twenty-two published adult cases of dermatomyositis and polymyositis associated with generalized subcutaneous edema (Table 1). Sixteen of these twenty-two patients had dermatomyositis, with a female predominance (11 females vs. 5 males), which is in keeping with the usual female to male ratio of 2:1 [3]. Despite aggressive treatment, patients frequently have a florid disease course, with significant morbidity and mortality. Improved survival more recently may be attributed to the increasing availability and usage of intravenous immunoglobulin (IV Ig). It is interesting to note that juvenile cases of dermatomyositis with significant angioedema have also been reported and these children demonstrate an aggressive clinical course and poor disease prognosis (4,5,6).

A unique feature of this edema is its localization. Our patient developed localized forearm swelling associated with increasing CK levels. Case reports have likened the acute appearance of localized edema to the clinical presentation of deep vein thrombosis [7,8,9]. The underlying pathogenesis for the subcutaneous edema remains to be elucidated. It has been thought that increased vascular permeability in the tissues and muscles leads to extensive leakage of fluid into surrounding structures [9]. This implies that subcutaneous edema may be a result of severe inflammation and an indirect indicator of aggressive disease. On the other hand, there may also be a role for an immune complex mediated vasculitis [10]. In juvenile cases of dermatomyositis, the deposition of immune complexes, complement activation, and vascular endothelial damage may all contribute to significant generalized edema [11].

Recently, evidence has emerged linking the pathogenesis of dermatomyositis to type I interferons. A case report of severe dermatomyositis exacerbated/induced by interferon beta therapy was published in 2008, supported by in vitro evidence of enhanced type 1 interferon signaling in response to interferon beta [12]. A 57-year-old man with multiple sclerosis and previous treatment with interferon beta-1a developed classical skin changes consistent with dermatomyositis, approximately five years after his last treatment [12].

The optimal treatment of dermatomyositis associated with subcutaneous edema remains unclear. The mainstay of therapy involves glucocorticoids, which are thought to act through anti-inflammatory and immunosuppressive effects [1,2]. However, additional immunosuppressive agents such as azathioprine and methotrexate are often employed as a more aggressive attempt to gain control of disease. IVIg has also been administered in severe, life threatening cases; eight out of nine patients given IVIg eventually recovered from their illness [8,9,13,14,15,16].

Newer biological agents have shown great promise in refractory cases of dermatomyositis. Rituximab has been successfully used in the treatment of refractory dermatomyositis and other inflammatory myopathies [17, 18]. There have not yet been any published case reports describing the use of rituximab in patients with generalized subcutaneous edema associated with dermatomyositis, but this remains an important therapeutic option to consider.

Conclusion

The presentation of dermatomyositis with significant subcutaneous edema is a clinical entity that needs to be highlighted because these cases are often associated with significant morbidity and mortality. We need to be aware that subcutaneous edema may be the first presenting feature of dermatomyositis. Although there has been a demonstrated response to glucocorticoid therapy, immunosuppressive agents, and IVIg, further information is needed to clarify optimal treatment of these patients and help elucidate the underlying pathogenesis of the disease.

References

1. Bohan A, Peter JB. Polymyositis and dermatomyositis (first of two parts). *N Engl J Med*. 1975 Feb 13;292(7):344-7. [PMID: 1090839]
2. Nitsche A, San Agustin PG, Amado V, Prina AP, Corsaro G. Trunk and Abdominal wall edema in dermatomyositis. *Medicina (B Aires)*. 1988; 48(3):331-2. [PMID: 2977631]
3. Dunkley L, Jawad A. Subcutaneous edema as a presenting feature of polymyositis / dermatomyositis: a poor prognostic indicator? *Rheumatology*. 2007; 7:21-25
4. Mourao AF, Pinto TL, Falcao Ribeiro C, Vieira H, Caetano-Lopes J, Nero P, dos Santos FP, Guimarães J, Branco JC. Juvenile dermatomyositis associated with anasarca - a clinical case. *Acta Reumatologica Portuguesa*. 2009 Apr-Jun;34(2A):276-80. [PMID: 19569283]
5. Saygi S, Alehan F, Baskin E, Bayrakci US, Ulu EM, Ozbek N. Juvenile dermatomyositis presenting with anasarca. *Journal of Child Neurology*. 2008 Nov; 23(11):1353-6. [PMID: 18984850]
6. Mitchell JP, Dennis GJ, Rider LG. Juvenile dermatomyositis presenting with anasarca: A possible indicator of severe disease activity. *Journal of Pediatrics*. 2001 Jun; 138(6):942-5. [PMID: 11391348]
7. Thurairajah P, Browne S, Bondeson J. A painful swollen calf. *J R Soc Med*. 2003 May;96(5): 236-237. [PMID: 12724436]
8. Gorelik O, Almoznino-Sarafian D, Alon I, Rapoport MJ, Goltsman G, Herbert M, Modai D, Cohen N. Acute inflammatory myopathy with severe subcutaneous edema, a new variant? Report of two cases and review of the literature. *Rheumatol Int*. 2001 May; 20(4): 163-6. [PMID: 11411962]
9. Chai Y, Bertorini TE, Li YD, Mitchell C, Guan H. Limb edema and anasarca associated with severe dermatomyositis: report of four cases. *Neuromuscul Disord*. 2011 Jun;21(6):439-42. [PMID: 21482469]
10. Andonopoulos AP, Gogos CA, Tzanakakis G. Subcutaneous Edema: an unrecognised feature of acute polymyositis. *Rheumatol Int*. 1993; 13(4):159-161. [PMID: 8310209]
11. Karabiber H, Aslan M, Alkan A, Yakinci C. A rare complication of generalized edema in juvenile dermatomyositis: a report of one case. *Brain and Development*. 2004 Jun; 26(4):269-272. [PMID: 15130694]
12. Somani, AK, Swick A, Cooper K, McCormick TS. Severe Dermatomyositis Triggered by Interferon Beta-1a Therapy and Associated With Enhanced Type I Interferon Signalling. *Arch Dermatol*. 2008 Oct; 144(10): 1341-1349. [PMID: 18936398]
13. Werner de Castro GR, Appenzeller S, Bértolo MB, Costallat LT. Acute dermatomyositis with subcutaneous generalized edema. *Clinical Rheumatology*, 2006 Nov, 25(6):898-900. [PMID: 16308667]
14. Lee KH, Lim SR, Kim YJ, Lee KJ, Myung DS, Jeong HC, Yoon W, Lee SS, Park YW. Acute dermatomyositis associated with generalized subcutaneous edema. *Rheumatol Int*, 2008 Jun; 28(8) :797-800. [PMID: 18193426]
15. Haroon M, Eltahir A, Harney S. Generalized subcutaneous edema as a rare manifestation of dermatomyositis: clinical lesson from a rare feature. *J Clin Rheumatol*. 2011 April;17(3):135-7. [PMID: 21441819]
16. Jung KD, Kim PS, Park HY, Kim CR, Byun JY, Lee DY, Lee JH, Yang JM, Lee ES. Dermatomyositis associated with generalized subcutaneous edema and Evans syndrome. *J Am Acad Dermatol*. 2012 Jan ;66(1):144-7. [PMID: 22030016]
17. Noss EH, Hausner-Sypek DL, Weinblatt ME, Rituximab as therapy for refractory polymyositis and dermatomyositis. *J Rheumatol*. 2006 May; 33:1021-1026. [PMID: 16541475]
18. Rios Fernandez R, Callejas Rubio JL, Sanchez Cano D, Sáez Moreno JA, Ortego Centeno N. Rituximab in the treatment of dermatomyositis and other inflammatory myopathies. A report of 4 cases and review of the literature. *Clin Exp Rheumatol*. 2009 Nov-Dec; 27(6):1009-16. [PMID: 20149324]