

# Febrile ulceronecrotic Mucha-Habermann disease—a case and treatment review

Sara Moutinho-Pereira<sup>1\*</sup>, Francisca Beires<sup>1\*</sup>, Joana dos Santos<sup>2</sup>, Maria Relvas<sup>3</sup>, Leonor Castendo Ramos<sup>3</sup>, Sara Castendo Ramos<sup>4</sup>, Teresa Medeiros<sup>1</sup>, Helena Greenfield<sup>1</sup>, Sara Augusta Ramos<sup>1</sup>, Pedro Andrade<sup>5</sup>

\*Authors contributed equally

Affiliations: <sup>1</sup>Departamento de Medicina, Serviço de Medicina Interna, Unidade Local de Saúde de Matosinhos EPE, Portugal, <sup>2</sup>Departamento de Meios Complementares de Diagnóstico e Terapêutica, Serviço de Anatomia Patológica, Unidade Local de Saúde de Matosinhos EPE, Portugal, <sup>3</sup>Departamento de Dermatologia, Centro Hospitalar e Universitário de Coimbra, Coimbra, Portugal, <sup>4</sup>Serviço de Cirurgia Plástica Reconstructiva e Queimados, Centro Hospitalar e Universitário de Coimbra, Portugal, <sup>5</sup>Departamento de Medicina, Serviço de Dermatologia, Unidade Local de Saúde de Matosinhos EPE, Portugal

Corresponding Author: Sara Moutinho-Pereira, Departamento de Medicina, Serviço de Medicina Interna, Rua Dr Eduardo Torres-Senhora da Hora, Matosinhos, Portugal, Tel: 351-229391000, Email: [sarasofia.pereira@gmail.com](mailto:sarasofia.pereira@gmail.com)

## Abstract

Febrile ulceronecrotic Mucha-Habermann disease is a rare and severe variant of pityriasis lichenoides, characterized by sudden onset of generalized ulceronecrotic papules that rapidly coalesce into ulcers associated with high fever. Systemic manifestations such as intravascular disseminated coagulation and pulmonary, cardiac, gastrointestinal, and central nervous system involvement are common. Treatment is based on oral corticosteroids, immunosuppressive drugs such as methotrexate, and general supportive treatment. The present case describes a stepwise approach to a patient with Mucha-Habermann disease with insufficient response to methotrexate.

*Keywords: dermatology, Mucha-Habermann, pityriasis lichenoides, PLEVA, ulceronecrotic*

## Introduction

The term “pityriasis lichenoides et varioliformis acuta” (PLEVA) was coined by Mucha in 1916 and Habermann in 1925, as an acute eruption of ulceronecrotic papules and plaques. Later in 1966, Degos et al. described a rare and severe variant of the term with a fulminant course and termed it febrile ulceronecrotic Mucha-Habermann disease (FUMHD),

[1]. This life-threatening variant of PLEVA is also known as PLEVA fulminans. Febrile ulceronecrotic Mucha-Habermann disease is distinguishable from the two most common types of pityriasis, PLEVA and pityriasis chronica [2]. It is characterized by a sudden onset of multiple generalized ulceronecrotic papules which rapidly coalesce into large ulcers associated with fever [3,4]. Systemic manifestations such as lymphadenopathy, pancytopenia, interstitial pneumonitis, cardiopathy, gastrointestinal dysfunction, central nervous system impairment, disseminated intravascular coagulation, sepsis, and rheumatological symptoms are frequently observed [3,5].

To our knowledge, only 135 cases of FUMHD have been previously described in literature, 43 in children and 92 in adults [6-9]. This rare disease is more prevalent in males (75%) and mostly affects children and young adults, having an estimated overall mortality rate of 12%. However, the mortality was significantly lower in children (2%) compared to adults (20%), [10], and death most commonly attributed to sepsis, cardiac arrest, hypovolemic shock, pulmonary thromboembolism, and massive thrombosis of the superior mesenteric artery [11]. Both fatal cases reported in children were associated with *Pseudomonas* septicemia [12,13]. A recent report described fatal lung involvement without

**Table 1.** Nofal criteria for diagnosis of pityriasis lichenoides et varioliformis acuta [12].

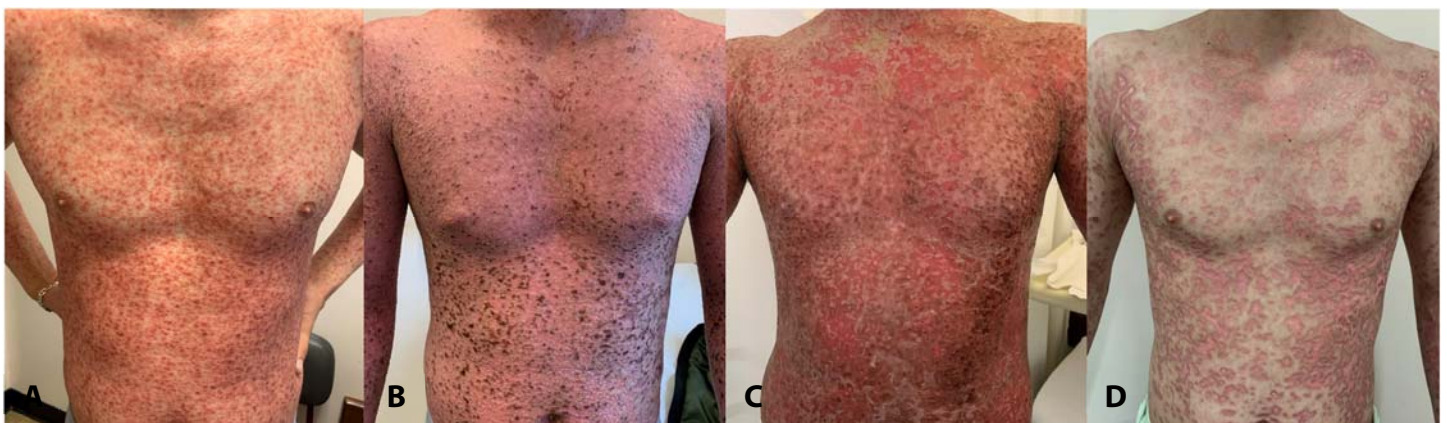Constant features	Fever Acute onset of generalized ulceronecrotic papules and plaques Rapid and progressive course without any tendency to spontaneous resolution Histopathology consistent with pityriasis lichenoides et varioliformis acuta
Variable features	Previous history of pityriasis lichenoides et varioliformis acuta Mucous membrane involvement Systemic involvement

evidence of thromboembolism [9]. The reason for better outcome in children remains elusive.

The etiology of FUMHD has not been fully established, but it probably results from an exacerbated inflammatory immune response to an infectious agent with immune complex deposition [4]. In a recent study, it was estimated that 17.6% of FUMHD cases had a potential trigger identified, most commonly infectious in etiology including mycoplasma [10], varicella zoster virus [14], parvovirus B19 [15], Epstein-Barr virus [16-18], herpes simplex virus 2 [19], cytomegalovirus [20], adenovirus type II [21], HIV, and human herpesvirus 7 [22]. Other potential non-infectious triggers include measles vaccine [23], spider bite [24], and drugs such as levamisole-adulterated cocaine [25], tegafur [26], and intravenous vitamin infusion [27]. Other studies suggested that FUMHD might be a variant of cutaneous T-cell lymphoma, owing to the observation of monoclonal T cells in these patients, which also correlated with a higher mortality [28]; this subject remains controversial. Other studies suggest that FUMHD might result from hypersensitivity vasculitis [29].

Clinically, FUMHD is a febrile dermatosis and may initially mimic several other conditions. The extensive list of conditions in the differential diagnosis includes Steven-Johnson syndrome [30], Kawasaki syndrome [31], hemorrhagic chickenpox infection, disseminated herpes zoster, coxsackievirus infection, syphilis, vasculitis, pyoderma gangrenosum, presumed pustular psoriasis [27], guttate psoriasis, lymphoid papulosis, hemorrhagic pityriasis rosea, bullous erythema multiforme, lichen planus, pemphigus vulgaris or paraneoplastic pemphigus, ecthyma gangrenosum, necrotic folliculitis, Gianotti-Crosti syndrome, erythema nodosum leprosum, blastomycosis, and malignant conditions involving clonal T cell proliferation [12,32-36].

Because FUMHD represents a challenging diagnosis and no unified criterion exists, Nofal *et al.* have proposed a subset of criteria comprised of constant features, which are found in every case of FUMHD and can confirm the diagnosis alone. In addition, variable features were identified to help ensure that cases of FUMHD are not missed (**Table 1**), [12,27]. Skin biopsy of a nonulcerated lesion of FUMHD



**Figure 1.** **A)** Ulceronecrotic lesions on the torso during hospital admission at day one after admission with papulopustular eruption. **B)** Evolution of lesions at day four with visible scaly lesions and crusts. **C)** Evolution of lesions at day 8 with ulceronecrotic lesions and epidermal detachment areas. **D)** Lesions at day 41 with re-epithelization and scarring.

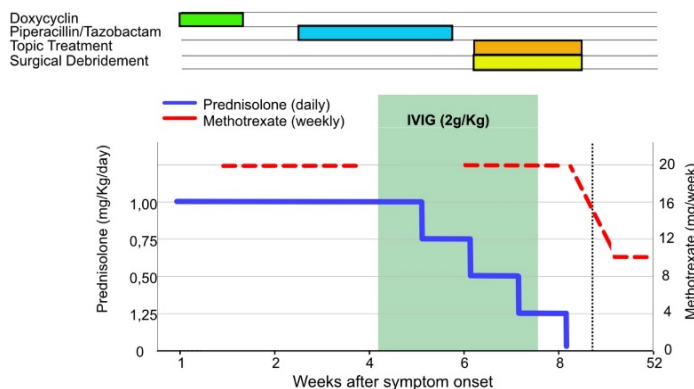
typically presents parakeratosis, spongiosis, and lymphocyte exocytosis, as well as lymphocytic vasculitis—histopathology findings commonly seen in PLEVA. Immunohistochemistry is nonspecific.

### Case Synopsis

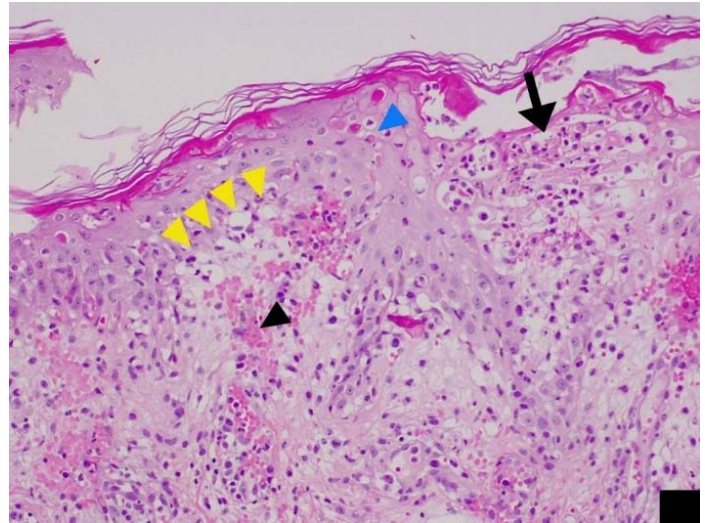
A 23-year-old healthy man was observed in the dermatology department presenting with a 2-week long febrile and pruriginous, papulopustular eruption, originally arising on the chest with centrifugal generalization, sparing palms, soles, and the face; some of these lesions were focally scaly and developed crusts, supporting the diagnosis of PLEVA (Figure 1). The patient denied taking any medication or having any relevant medical conditions in the precedent weeks. There was no personal or familial history of autoimmune or dermatologic diseases.

Treatment was started on oral prednisolone (1mg/kg/day) and doxycycline (100mg once daily), (Figure 2) but the patient was soon admitted to an internal medicine ward following rapid progression of the disease, with the development of fever and large coalescent painful ulceronecrotic lesions extending to his genital area. Nikolsky sign was negative.

A skin biopsy revealed marked inter- and intracellular edema in the epidermis accompanied by keratinocyte necrosis and hydropic degeneration (Figure 3). Exocytosis was prominent and intraepidermal red blood cells were present. The upper and deep dermis contained a perivascular



**Figure 2.** Different treatments during hospital admission, including antibiotics for opportunistic infections, alongside with corticosteroid daily prednisolone, weekly methotrexate and IV immunoglobulin for 20 days.



**Figure 3.** H&E histopathology of skin biopsy. There is severe spongiosis (arrow) with lymphocytic exocytosis, red cell extravasation (black arrowhead), hydropic degeneration (yellow arrowheads), and apoptotic keratinocytes, 200x.

lymphocytic inflammatory infiltrate. No eosinophils or Munro microabscesses were observed.

The patient was then started on 20mg parenteral methotrexate (MTX) weekly. Both *Enterobacter cloacae* complex and *Pseudomonas aeruginosa* were isolated in hemocultures, justifying systemic antibiotic treatment with piperacillin-tazobactam. Blood analysis revealed leukocytosis (13000/uL) and elevated levels of C-reactive protein (115mg/l), procalcitonin (1.92ng/l) and IgE (746U/l). Viral serologies were negative for Epstein-Barr virus, cytomegalovirus, parvovirus, HIV, herpes simplex, varicella-zoster virus, and hepatitis B and C viruses.

Progressive clinical deterioration was observed in the following days, with aggravation of epidermal detachment areas on the torso affecting 15-20% of total body surface (Figure 1C, D). The patient was transferred to the burn unit of a specialized plastic surgery department for regular surgical debridement and optimized topical treatment. In our patient, collaborative management with other specialties resulted in the admission to the burn unit; however, this approach would not be necessary in general for patients with febrile ulceronecrotic PLEVA. Following two weeks of MTX treatment, the absence of clinical improvement and the significant elevation of liver enzymes (aspartate aminotransferase/alanine aminotransferase 176/325U/l,



respectively; normal 5-40U/l and 4-56U/l, respectively) led us to suspend MTX. The patient was then started on weekly intravenous immunoglobulin 2g/kg (IVIg) over 20 days and evolved favorably, with gradual re-epithelization of the lesions and extensive scarring, allowing progressive reduction of prednisolone dose, while maintaining therapy with IVIg and restarting MTX. Hospital discharge was possible 29 days after admission to the burn unit.

During follow-up, recurrent generalized papular crusted lesions consistent with pityriasis lichenoides chronica were frequently observed, justifying a slow tapering of the prednisolone and MTX treatment. At present, over two years after admission, low dose MTX (10mg/week) is still necessary to control the inflammatory activity of the disease.

## Case Discussion

Febrile ulceronecrotic Mucha-Habermann disease is a rare and potentially life-threatening disease if left untreated. Several treatment options have been described, such as oral corticosteroids, tetracyclines, acyclovir, MTX, cyclosporine, dapsone, TNF inhibitors, IVIg, plasmapheresis, and phototherapy (Table 2). Corticosteroids and MTX have been more frequently used in recent years [2,6]. However, because FUMHD is so rare and many times, multiple therapies are often administered simultaneously to these patients, there is no consensus on a recommended treatment algorithm and the best approach to this disease is unknown. A recent literature review by Liu et al., discusses the clinical features, therapies, and outcomes in 42 children with FUMHD [6]. In more than one case that failed initial systemic therapy, MTX showed excellent results [38,6]. Another recent systematic review that includes children and adults focused on mortality risk factors in FUMHD and therapeutic outcomes and complications [39].

The documentation of predominant CD8+ and/or CD3 T cell infiltration of lesional skin of patients with FUMHD, indicates a dysregulated T cell response following a possible trigger [40]. Additionally, the transition from PLEVA to FUMHD is associated with high serum levels of TNF [41], IL6, IL8, IL10, interferon-gamma [42]. Based on these findings,

targeted immunotherapy has emerged using antibodies blocking TNF, such as infliximab [32,43]. More recently, tocilizumab (an IL6 inhibitor) and ruxolitinib (a JAK inhibitor) were successfully used to treat a 7-year-old boy [43], and basiliximab (IL2 inhibitor) to treat a 5-year-old girl with T cell acute lymphoblastic leukemia and FUMHD [33].

Intravenous immunoglobulin, also used to treat FUMHD, has had mixed results. The exact mechanism of action of IVIg is unknown but IVIg therapy aims to replenish sufficient amounts of IgG antibodies that passively neutralize or opsonize a broad spectrum of pathogens and could also elicit an active immune response via activation of various immune cells [44]. Also, high-dose IVIg take an active part and modulate the immune functions with additional anti-inflammatory activity. Given its overall safety profile and apparent efficacy in pediatric cases, use of IVIg in FUMHD may be warranted. [45]. Intravenous immunoglobulin has been used also in the adult population with good results, as is the case of our patient, in whom MTX had to be suspended owing to liver enzyme elevation. Thus, given the absence of guidelines to treat FUMHD and the heterogeneity of clinical response to different medications, in certain cases, a personalized stepwise approach is needed.

Several risk factors have been associated with a poor prognosis of FUMHD patients and in 2021, Blohm et al. suggested a mortality risk score based on increased age, systemic involvement, sepsis, and mucosal involvement increasing the mortality risk [10]. Febrile ulceronecrotic Mucha-Habermann disease-S mortality risk score ("S" because it included the factor "sepsis") was discriminative for a fatal outcome at a sensitivity of 93% and a specificity of 89%, and was proposed as follows: FUMHD-S mortality score = age[years]/10+1+5 (if sepsis present)+4 (if systemic involvement present)+1(if mucosal involvement present), [10]. Both pediatric and adult patients with a FUMHD mortality risk score  $\geq 10$  may benefit from an early transfer to an appropriate intensive care unit. Later, a systematic review found no association of mucosal involvement and mortality risk [39]. Also, monoclonal T cell receptor rearrangement was generally associated with a higher mortality risk [10].

Febrile ulceronecrotic Mucha-Habermann disease recurrences have been reported in literature, though are less severe than the primary episode. On a recent review, follow-up of 45 patients ranged from two weeks to 5 years, with recurrence being associated with the discontinuation of medication, more specifically MTX [39]. The authors suggest a follow-up of patients of at least 9 months to accurately represent the likelihood of recurrence. Methotrexate is the most commonly prescribed medication for maintenance therapy in FUMDH [39].

## Conclusion

Pityriasis lichenoides et varioliformis acuta is a rare cutaneous disorder whose pathogenesis is not well

understood, being viewed either as a benign lymphoproliferative disorder or as a hypersensitivity response to infection. Febrile ulceronecrotic Mucha-Habermann disease is an infrequent and severe variant of PLEVA, characterized by large skin ulcerations, fever, and systemic illness with organ involvement. The reported case highlights the importance of early diagnosis and rapid establishment of proper aggressive treatment for the successful management of this potentially fatal disease.

## Potential conflicts of interest

The authors declare no conflicts of interest.

## References

1. Degos R, Duperrat B, Daniel F. The ulceronecrotic parapsoriasis with hyperthermia. *Ann Dermatol Venereol* 1966;93:481-96. [PMID: 5972274].
2. Tang P, Chen J, Wang H, Yang H. Febrile Ulceronecrotic Mucha-Habermann Disease: A case report and a systematic review. *Case Rep Dermatol*. 2022;169-177. [PMID: 35950146].
3. Bica BE, de Barros Mda G, Spingola C Jr. Mucha-Habermann disease. *Rev Bras Reumatol*. 2013;53:314-7. [PMID: 24051916].
4. Keeratimahat A, Sudtikoonaseth P, Jaovisidha S. A case report of febrile ulceronecrotic Mucha-Habermann disease in Thailand. *Thai J Dermatol*. 2016;32:224-229.
5. Miyamoto T, Takayama N, Kitada S, Hagari Y, Mihara M. Febrile ulceronecrotic Mucha-Habermann disease: a case report and a review of the literature. *J Clin Pathol*. 2003;56:795-7. [PMID: 14514790].
6. Liu J, Zhong J, Wang Q, Cai Y, Chen J. Febrile ulceronecrotic Mucha-Habermann disease: a case report and review of literature in the paediatric population. *Acta Derm Venereol*. 2023;19:103:adv4806. [PMID: 37073962].
7. Avcı C, Gürbüz Ö, Özbağcıvan Ö, Lebe B. Febrile ulceronecrotic Mucha-Habermann disease during pregnancy: A case report. *Australas J Dermatol*. 2023;64:245-248. [PMID: 37002720].
8. Rai E, Kamzan A, Boozalis E, Hogeling M, Fong K. A case of febrile ulceronecrotic Mucha-Habermann disease responsive to systemic corticosteroids. *Pediatr Dermatol*. 2023;40:573-575. [PMID: 36573550].
9. Alhawsawi W, Al Hawsawi K, Almahdi B, et al. A diagnostically challenging case of de novo febrile ulceronecrotic Mucha-Habermann disease with fatal pulmonary involvement: a case report. *Case Rep Dermatol*. 2023;15:17-21. [PMID: 36686043].
10. Blohm ME, Ebenebe CU, Rau C, et al. Mucha-Habermann disease: a pediatric case report and proposal of a risk score. *Int J Dermatol*. 2022;61:401-409. [PMID: 34287852].
11. Sotiriou E, Patsatsi A, Tsorova C, Lazaridou E, Sotiriadis D. Febrile ulceronecrotic Mucha-Habermann disease: a case report and review of the literature. *Acta Derm Venereol*. 2008;88:350-5. [PMID: 18709304].
12. Nofal A, Alakad R, Assaf M, Nofal E. A fatal case of febrile ulceronecrotic Mucha-Habermann disease in a child. *JAAD Case Rep*. 2016;2:181-5. [PMID: 27222883].
13. Singh GK, Arora S, Das P, Gupta A. A fatal case of febrile ulceronecrotic Mucha-Habermann disease in a 10-year-old boy. *Indian Dermatol Online J*. 2022;13:535-538. [PMID: 36262572].
14. Hervás JA, Martín-Santiago A, Hervás D, et al. Varicella precipitating febrile ulceronecrotic Mucha-Habermann disease. *Pediatr Dermatol*. 2013;30:e216-7. [PMID: 23106817].
15. Nanda A, Alshalfan F, Al-Otaibi M, Al-Sabah H, Rajy JM. Febrile ulceronecrotic Mucha-Habermann disease (pityriasis lichenoides et varioliformis acuta fulminans) associated with parvovirus infection. *Am J Dermatopathol*. 2013;35:503-6. [PMID: 23612031].
16. Helbling I, Chalmers RJ, Yates VM. Febrile ulceronecrotic Mucha-Habermann disease: a rare dermatological emergency. *Clin Exp Dermatol*. 2009;34:e1006-7. [PMID: 20055819].
17. Ricci G, Patrizi A, Misciali D, Masi M. Pathological case of the month. Febrile Mucha-Habermann disease. *Arch Pediatr Adolesc Med*. 2001;155:195-6. [PMID: 11177098].
18. Yang CC, Lee JY, Chen W. Febrile ulceronecrotic Mucha-Habermann disease with extensive skin necrosis in intertriginous areas. *Eur J Dermatol*. 2003;13:493-6. [PMID: 14693498].
19. Smith JJ, Oliver GF. Febrile ulceronecrotic Mucha-Habermann disease associated with Herpes simplex virus type 2. *J Am Acad Dermatol*. 2009;60:149-52. [PMID: 19103367].
20. Tsai KS, Hsieh HJ, Chow KC, et al. Detection of cytomegalovirus infection in a patient with febrile ulceronecrotic Mucha-Habermann's disease. *Int J Dermatol*. 2001;40:694-8. [PMID: 11737435].
21. Auster BI, Santa Cruz DJ, Eisen AZ. Febrile ulceronecrotic Mucha-Habermann's disease with interstitial pneumonitis. *J Cutan Pathol*. 1979;6:66-76. [PMID: 438396].
22. Costa-Silva M, Calistru A, Sobrinho-Simões J, Lisboa C, Azevedo F. Pityriasis lichenoides et varioliformis acuta associated with Human Herpesvirus 7. *Actas Dermosifiliogr*. 2018;109:e6-e10. [PMID: 29221609].
23. Zhang LX, Liang Y, Liu Y, Ma L. Febrile ulceronecrotic Mucha-

- Habermann's disease with pulmonary involvement. *Pediatr Dermatol.* 2010;27:290-3. [PMID: 20609148].
24. Lejuste FX, Michaux C, Lehnens C, Calteux N. Febrile ulceronecrotic Mucha-Habermann disease. *BMJ Case Rep.* 2013;bcr2013009739. [PMID: 24127370].
  25. Fongue J, Amatore F, Benzaquen M, et al. Febrile ulceronecrotic Mucha-Habermann disease after levamisole-adulterated cocaine use: an unusual case. *Clin Exp Dermatol.* 2018;43:846-848. [PMID: 29851134].
  26. Kawamura K, Tsuji T, Kuwabara Y. Mucha-Habermann disease-like eruptions due to Tegafur. *J Dermatol.* 1999;26:164-7. [PMID: 10209923].
  27. Ngo T, Hossain C, Cohen J, et al. A diagnostically challenging case of febrile ulceronecrotic Mucha-Habermann disease in an adult female successfully treated with methotrexate and cyclosporine. *Case Rep Dermatol.* 2021;13:12-17. [PMID: 33613228].
  28. Cozzio A, Hafner J, Kempf W, et al. Febrile ulceronecrotic Mucha-Habermann disease with clonality: a cutaneous T-cell lymphoma entity? *J Am Acad Dermatol.* 2004;51:1014-7. [PMID: 15583604].
  29. Arakawa H, Nakayama H, Chen KR. Lymphocytic vasculitis in pityriasis lichenoides et varioliformis acuta. *Australas J Dermatol.* 2020;61:e428-e430. [PMID: 32309878].
  30. Maria Sälävästru C, Severin E, Moisa M, Fritz K, Tiplica S. Extreme dermatology – the intensive care skills of dermatologists in three case presentations of acute skin failure. *Acta Dermatovenerol Croat.* 2014;22:44-7. [PMID: 24813841].
  31. Weins AB, Theiler M, Bogatu B, et al. Febrile ulceronecrotic Mucha-Habermann disease mimicking Kawasaki disease. *J Dtsch Dermatol Ges.* 2020;18:140-142. [PMID: 31814284].
  32. Meziane L, Caudron A, Dhaille F, et al. Febrile ulceronecrotic Mucha-Habermann disease: treatment with infliximab and intravenous immunoglobulins and review of the literature. *Dermatology.* 2012;225:344-8. [PMID: 23391565].
  33. Orenstein LAV, Coughlin CC, Flynn AT, et al. Severe Mucha-Habermann-like ulceronecrotic skin disease in T-cell acute lymphoblastic leukemia responsive to basiliximab and stem cell transplant. *Pediatr Dermatol.* 2017;34:e265-e270. [PMID: 28884915].
  34. Muller SA, Schulze TW Jr. Mucha-Habermann disease mistaken for reticulum cell sarcoma. *Arch Dermatol.* 1971;103:423-7. [PMID: 4933383].
  35. Verallo VM, Haserick JR. Mucha-Habermann's disease simulating lymphoma cutis. Report of two cases. *Arch Dermatol.* 1966;94:295-9. [PMID: 4951810].
  36. Sheng N, Li Z, Su W, et al. A Case of Primary Cutaneous Aggressive Epidermotropic CD8+ Cytotoxic T-cell lymphoma misdiagnosed as febrile ulceronecrotic Mucha-Habermann disease. *Acta Derm Venereol.* 2016;96:136-7. [PMID: 26039505].
  37. Bhide DS, Tulpule MS, Pethe SV. A case of febrile ulceronecrotic Mucha-Habermann disease with comorbidities. *Indian J Dermatol Venereol Leprol.* 2019;85:660-663. [PMID: 30860167].
  38. Griffith-Bauer K, Leitenberger SL, Krol A. Febrile ulceronecrotic Mucha-Habermann disease: two cases with excellent response to methotrexate. *Pediatr Dermatol.* 2015;32:e307-8. [PMID: 26584702].
  39. Tasouli-Drakou V, Nguyen M, Guinn H, et al. Mortality risk factors in febrile ulceronecrotic Mucha-Habermann disease: A systematic review of therapeutic outcomes and complications. *Dermatol Reports.* 2022;14:9492. [PMID: 36483219].
  40. Lode HN, Döring P, Lauenstein P, et al. Febrile ulceronecrotic Mucha-Habermann disease following suspected hemorrhagic chickenpox infection in a 20-month-old boy. *Infection.* 2015;43:583-8. [PMID: 25627543].
  41. Tsianakas A, Hoeger PH. Transition of pityriasis lichenoides et varioliformis acuta to febrile ulceronecrotic Mucha-Habermann disease is associated with elevated serum tumour necrosis factor-alpha. *Br J Dermatol.* 2005;152:794-9. [PMID: 15840118].
  42. Wu R, DiLorenzo A, Lotke M, et al. Evaluation and treatment of febrile ulceronecrotic Mucha-Habermann disease with ruxolitinib and tocilizumab as guided by cytokine profile. *JAMA Dermatol.* 2021;157:1381-1383. [PMID: 34643656].
  43. Kreuter A, Knispel S, Wieland U, Oellig F, Tigges C. Complete resolution of febrile ulceronecrotic Mucha-Habermann disease following infliximab therapy. *J Dtsch Dermatol Ges.* 2016;14:184-6. [PMID: 26790133].
  44. Arumugham VB, Rayi A. Intravenous Immunoglobulin (IVIg). 2022 Jul 4. In: StatPearls [Internet]. Treasure Island (FL): StatPearls Publishing; 2023. [PMID: 32119333].
  45. Perrin BS, Yan AC, Treat JR. Febrile ulceronecrotic Mucha-Habermann disease in a 34-month-old boy: a case report and review of the literature. *Pediatr Dermatol.* 2012;29:53-8. [PMID: 21906156].
  46. Zimmer KA, Clay T, Burkemper NM. Febrile ulceronecrotic Mucha-Habermann disease: a rare form of pityriasis lichenoides et varioliformis acuta. *Cutis.* 2022;109:E8-E11. [PMID: 35180060].
  47. Rasmussen JE. Mucha-Habermann's disease. *Arch Dermatol.* 1979;115:676-7. [PMID: 453866].
  48. Cornelison RL Jr, Knox JM, Everett MA. Methotrexate for the treatment of Mucha-Habermann disease. *Arch Dermatol.* 1972;106:507-8. [PMID: 5079356].
  49. Lazaridou E, Fotiadou C, Tsorova C, et al. Resistant pityriasis lichenoides et varioliformis acuta in a 3-year-old boy: successful treatment with methotrexate. *Int J Dermatol.* 2010;49:215-7. [PMID: 20465649].
  50. Lynch PJ, Saied NK. Methotrexate treatment of pityriasis lichenoides and lymphomatoid papulosis. *Cutis.* 1979;23:634-6. [PMID: 456031].
  51. Marengo F, Fava P, Fierro MT, Quaglino P, Bernengo MG. High-dose immunoglobulines and extracorporeal photochemotherapy in the treatment of febrile ulceronecrotic Mucha-Habermann disease. *Dermatol Ther.* 2010;23:419-22. [PMID: 20666830].
  52. Pырpasopoulou A, Athyros VG, Karagiannis A, Chrysomallis F, Zamboulis C. Intravenous immunoglobulins: a valuable asset in the treatment of a case of septic febrile ulceronecrotic Mucha-Habermann disease. *Dermatology.* 2007;215:164-5. [PMID: 17684382].
  53. Herron MD, Bohnsack JF, Vanderhooft SL. Septic, CD30 positive febrile ulceronecrotic pityriasis lichenoides et varioliformis acuta. *Pediatr Dermatol.* 2005;22:360-5. [PMID: 16060878].
  54. Kim HS, Yu DS, Kim JW. A case of febrile ulceronecrotic Mucha-Habermann's disease successfully treated with oral cyclosporin. *J Eur Acad Dermatol Venereol.* 2007;21:272-3. [PMID: 17243979].
  55. Uzoma MA, Wilkerson MG, Carr VL, Westhoven GS, Raimer SA. Pentoxifylline and cyclosporine in the treatment of febrile ulceronecrotic Mucha-Habermann disease. *Pediatr Dermatol.* 2014;31:525-7. [PMID: 23005254].
  56. Rosman IS, Liang LC, Patil S, Bayliss SJ, White AJ. Febrile ulceronecrotic Mucha-Habermann disease with central nervous system vasculitis. *Pediatr Dermatol.* 2013;30:90-3. [PMID: 22276640].
  57. De Cuyper C, Hindryckx P, Deroo N. Febrile ulceronecrotic pityriasis lichenoides et varioliformis acuta. *Dermatology.* 1994;189 Suppl 2:50-3. [PMID: 7841557].
  58. López-Estebarez JL, Vanaclocha F, Gil R, García B, Iglesias L. Febrile ulceronecrotic Mucha-Habermann disease. *J Am Acad Dermatol.* 1993;29:903-6. [PMID: 8408838].

59. Houghton MA, Ellis JP, Hayes MJ. Febrile ulceronecrotic Mucha-Habermann disease: a fatality. *J R Soc Med.* 1989;82:500-1. [PMID: 2778784].

**Table 2.** Systemic treatment options for febrile ulceronecrotic Mucha-Habermann disease.

		Dose	Frequency	Duration	Adult/ Pediatric	References
Systemic corticosteroids	Prednisolone	1-2mg/kg	Daily	NS	Pediatric; adult; adult	Perrin et al. [45]; Bhide et al. [37] and present case
		60mg	Daily	NS	Adult	Meziane et al. [32]
		80mg	Daily	NS	Adult	Zimmer et al. [46]
	Methylprednisolone	60mg (iv)	Daily	NS	Pediatric	Liu et al. [6]
	Methylprednisolone pulses	300mg (iv) at day1, 200mg at day 2, 100mg at day 3	Daily	3 days	Pediatric	Liu et al. [6]
		120mg	Daily	5 days	Adult	Lejuste et al. [24]
		500mg	Daily	3 days	Adult	Bica et al. [3]
		15mg/kg	Daily	3 days	Pediatric	Singh et al. [13]
Dexamethasone	3mg/m <sup>2</sup>	Twice daily	NS	Pediatric	Orenstein et al. [33]	
Methotrexate	7.5-20mg	Weekly	NS	Pediatric; adult; pediatric; adult	Rasmussen [47]; Cornelison et al. [48]; Lazaridou et al. [49]; Lynch and Saied [50]	
	15mg (iv)	Weekly	6 weeks; two months	Pediatric; pediatric; adult	Perrin et al. [45]; Liu et al.[6], Sotiriou et al. [11]	
	12mg	Weekly	**	Adult	Meziane et al. [32]	
	20mg	Weekly	NS	Adult; adult	Ngo et al. [27] and present case	
	0.5mg/kg	Weekly	5 months	Pediatric	Wu et al. [42]	
	20mg/m <sup>2</sup>	Weekly	NS	Pediatric	Orenstein et al. [33]	
	10mg/m <sup>2</sup>	Weekly	NS	Adult	Marenco et al. [51]	
	10mg*	Weekly	2 years	Adult	Sotiriou et al. [11] and present case	
	5mg*	Weekly	NS	Pediatric	Perrin et al. [45]	
Intravenous Immunoglobulins	400mg/kg	Daily	5 days	Adult	Marenco et al. [51]	
	2g/kg	Weekly	20 days	Adult	Present case	
	2mg/kg	Weekly	2 weeks and then once monthly	Adult	Meziane et al. [32]	
	2g/kg	Daily	3 days 2 days	Pediatric; pediatric;	Perrin et al. [45]; Singh et al. [13]; Blohm et al. [10].	



				pediatric; pediatric	Pyrpasopoulou et al. [52]
	1g/kg	Daily	2 days	Pediatric	Orenstein et al. [33]
Cyclosporin	3-6mg/kg	Daily	NS	Pediatric	Herron et al. [53]
	2.5mg/kg	Daily	4 days	Pediatric	Kim et al. [54]
	4mg/kg	Twice daily	NS	Adult	Ngo et al. [27]
	150mg (oral)	Twice daily	NS	Adult	Ngo et al. [27]
	150mg (oral)	Daily	5 weeks	Adult, pediatric	Uzoma et al. [55]
Cyclophosphamide	1000mg/m <sup>2</sup>	NS	NS	Pediatric	Rosman et al. [56]
Dapsone	NS	NS	NS	Pediatric	Perrin et al. [45]
Pentoxifylline	400mg (oral)	Three times per day	2 months	Adult, pediatric	Uzoma et al. [55]
Infliximab	5mg/kg	Weekly	4 weeks	Adult	Meziane et al. [32]
	5mg/kg*	Every 6 weeks	1 year	Adult	Meziane et al. [32]
Basiliximab	12mg/m <sup>2</sup>	Weekly	4 weeks		Orenstein et al. [33]
Tocilizumab	8mg/kg	Every two weeks	5 months	Pediatric	Wu et al. [42]
Ruxolitinib	5-10mg	Twice daily	5 months	Pediatric	Wu et al. [42]
Etanercept	NS	NS	NS	Pediatric	Wu et al. [42]
Phototherapy (PUVA, NBUBV, photoimmunotherapy and extracorporeal phototherapy)	variable	-	-	Adult; pediatric; pediatric; adult; adult; adult; adult	De Cuyper et al.[57]; Hervás et al.[14]; Nanda et al.[15]; Tsai et al. [20]; Cozzio et al. [28]; López-Esteban; [58] Marenco et al. [51]; Houghton et al. [59]

Systemic antibiotics/antivirals/antifungals may be used if there is evidence of infection.

\*Maintenance dose.

\*\* rapidly discontinued because of pancytopenia and renal insufficiency.

iv, intravenous; NS, not specified.