

# Hitchhiking spider: a case of unilateral vasculitis

Malina Yamashita Peterson<sup>1,2</sup> BS, Joohee Han<sup>1</sup> MD, Michelle Xiong<sup>1,3</sup> BS, Robert Werling<sup>1</sup> MD, Anne Neeley<sup>1</sup> MD, Joseph Scherman<sup>1</sup> MD, Anna Kozlowski<sup>1</sup> MD

Affiliations: <sup>1</sup>Department of Dermatology, HealthPartners Institute, Minneapolis, Minnesota, USA, <sup>2</sup>University of Minnesota Medical School, Minneapolis, Minnesota, USA, <sup>3</sup>Warren Alpert Medical School, Brown University, Providence, Rhode Island, USA

Corresponding Author: Anna Kozlowski MD, Park Nicollet Dermatology Clinic, 3800 Park Nicollet Boulevard, Suite 400, St. Louis Park, MN 55416; Tel: 701-261-5658, Email: [anna.m.kozlowski@healthpartners.com](mailto:anna.m.kozlowski@healthpartners.com)

## Abstract

A 63-year-old man presented with two days of palpable purpura over the right anterior shin and calf with notable point tenderness on the distal mid-calf without any palpable deep abnormality. Localized right calf pain worsened with walking and was associated with headache, chills, fatigue, and low-grade fevers. A punch biopsy of the anterior right lower leg showed necrotizing neutrophilic vasculitis of superficial and deep vessels. Direct immunofluorescence showed non-specific focal granular deposition of C3 within vessel walls. Three days after presentation, a live spider was found and microscopically identified as a male hobo spider. The patient suspected the spider arrived via packages shipped from Seattle, Washington. The patient was treated with a prednisone taper with full resolution of his cutaneous symptoms. Given the unilaterality of his symptoms and otherwise unexplained etiology, the patient was diagnosed with acute unilateral vasculitis secondary to hobo spider bite. Microscopic examination is required for identification of hobo spiders. Although not deadly, there have been several reports of cutaneous and systemic reactions resulting from hobo spider bites. Our case illustrates the importance of considering hobo spider bites in areas outside of their native regions, as they are known to travel in packaged items.

Keywords: bite, hobo spider, vasculitis

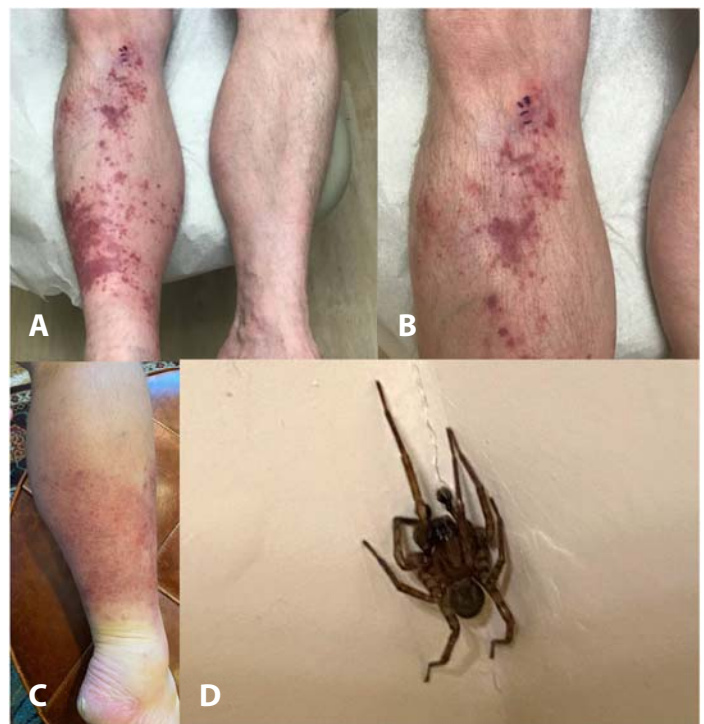## Introduction

Dermatologic reactions secondary to spider bites can be difficult to diagnose and manage because

spiders must be identified by a qualified professional. Herein, we highlight a case of unilateral vasculitis with a professionally identified hobo spider.

## Case Synopsis

A 63-year-old man with history of well-controlled psoriasis presented with two days of palpable purpura over the right anterior shin and calf with notable point tenderness on the distal mid-calf without any palpable deep abnormality (**Figure 1A-**



**Figure 1.** Clinical images of unilateral vasculitis secondary to possible hobo spider bite. **A-B)** Palpable purpura over the right anterior shin onto the calf, **C)** with a significant localized pain over the distal mid-calf. **D)** The possible suspect, hobo spider.

C). Localized right calf pain worsened with walking and was associated with headache, chills, fatigue, and low-grade fevers. Clinical history was negative for recent immobilization or hematologic disease.

Venous ultrasound of the right calf was negative for deep vein thrombosis. Laboratory studies showed mild leukocytosis as well as slight elevations of C-reactive protein, erythrocyte sedimentation rate, and C3 complement. Antibody studies associated with autoimmune diseases were negative. Malignancy screens were negative. Blood cultures, hepatitis panel, and HIV antigen, and antibody were negative.

A four mm punch biopsy of the anterior right lower leg showed necrotizing neutrophilic vasculitis of superficial and deep vessels (**Figure 2**). Direct immunofluorescence showed non-specific focal granular deposition of C3 within vessel walls.

Three days after presentation, the patient took a photo of a live spider found in his home (**Figure 1D**). An entomologist, employed by the patient's home pest service, microscopically identified the arachnid as a male hobo spider. The patient suspected the spider arrived via packages shipped from his son in Seattle, Washington.

The patient was treated with a prednisone taper and hydrocortisone 2.5% ointment with full resolution of his cutaneous symptoms and without residual complications. Repeat labs were within normal limits. No recurrence of cutaneous symptoms has been reported in the last seven months since home extermination of the spider.

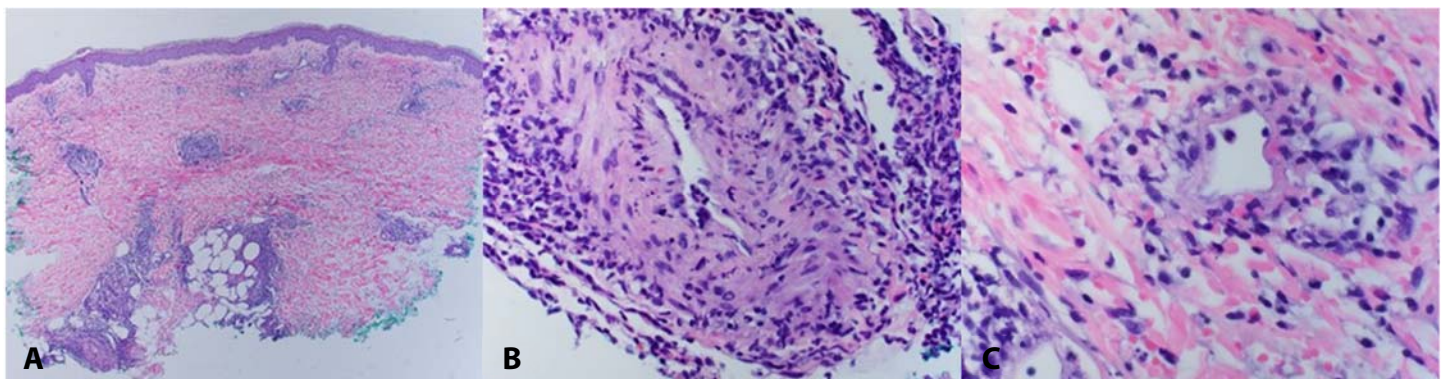
Given the unilaterality of his symptoms and otherwise unexplained etiology, the patient was diagnosed with acute unilateral vasculitis secondary to hobo spider bite. Interestingly, another hobo spider was found as the shipped boxes were fully unpacked.

## Case Discussion

Native to Europe, hobo spiders (*Eratigena agrestis*) can be found in Montana, Wyoming, Colorado, as well as the Pacific Northwest region of the United States, where the patient's son had packaged items for shipping [1]. The name "hobo" was given as the spider traveled between cities by railway systems [2]. As hobo spiders cannot be accurately distinguished from other spider species grossly, microscopic examination of reproductive structures by qualified arachnologists is required for definitive identification [2].

Whether hobo spider bites are of medical or dermatologic significance has been controversial and the hobo spider was removed from the official list of venomous spiders by the Centers for Disease Control and Prevention [3]. However, a 2004 literature review on hobo spider bites found one verified bite resulting in phlebitis and skin necrosis [4]. Furthermore, a 2014 study identified another bite associated with pain, erythema, and leg fasciculation [5]. Headache has also been reported [2].

Hobo spiders are often confused with other spiders, like the brown recluse spider, *Loxosceles reclusa*,



**Figure 2.** Photomicrographs of necrotizing neutrophilic vasculitis of superficial and deep vessels. H&E histopathology demonstrates a neutrophilic inflammation of dermal blood vessel, with associated mural fibrinoid necrosis, intramural neutrophils, and prominent erythrocyte extravasation. **A)** 4x; **B)** 40x; **C)** 40x.

which is much more poisonous [6]. The initial bite of a brown recluse spider is typically painless, although some patients describe sharp pain or burning. Progression of potential skin necrosis from recluse spider bites typically occurs over several days with healing over weeks.

Treatment for spider bites consists of cleansing of the site, analgesia for mild to moderate pain, and tetanus prophylaxis as appropriate. No consensus exists for treatments other than supportive care [6]. Collection and identification of the spider is paramount to establishing a diagnosis and allows for discernment of venomous potential.

## References

1. Vetter RS, Roe AH, Bennett RG, et al. Distribution of the medically-implicated hobo spider (Araneae: Agelenidae) and a benign congener, *Tegenaria duellica*, in the United States and Canada. *J Med Entomol.* 2003;40:159-164. [PMID: 12693843].
2. Vetter RS. Hobo Spider. November, 2015. <http://ipm.ucanr.edu/PMG/PESTNOTES/pn7488.html>. Accessed on March 18, 2022.
3. Types of venomous spiders. May 31, 2018.

## Conclusion

We highlight a case of unilateral palpable purpura with few systemic symptoms, likely explained by a hobo spider bite. Although not deadly, there have been several reports of cutaneous and systemic reactions resulting from their bites. Our case illustrates the importance of considering hobo spider bites in areas outside of their native regions, as they are known to travel in packaged items.

## Potential conflicts of interest

The authors declare no conflicts of interest

4. <https://www.cdc.gov/niosh/topics/spiders/types.html>. Accessed on March 18, 2022.
4. Vetter RS, Isbister GK. Do hobo spider bites cause dermonecrotic injuries?. *Ann Emerg Med.* 2004;44:605-607. [PMID: 15573036].
5. McKeown N, Vetter RS, Hendrickson RG. Verified spider bites in Oregon (USA) with the intent to assess hobo spider venom toxicity. *Toxicon.* 2014;84:51-55. [PMID: 24726469].
6. Swanson DL, Vetter RS. Bites of brown recluse spiders and suspected necrotic arachnidism. *N Engl J Med.* 2005;352:700-707. [PMID: 15716564].