

Bullous lupus erythematosus with an erythema gyratum repens-like pattern

Ana Cristina da Silva Sousa¹, Manuel Campos¹, Ana Oliveira¹, Nuno Menezes¹, David Tente², Armando Baptista¹

Affiliations: ¹Department of Dermatology, Centro Hospitalar Vila Nova de Gaia/Espinho, Vila Nova de Gaia, Portugal, ²Department of Anatomopathology, Centro Hospitalar Vila Nova de Gaia/Espinho, Vila Nova de Gaia, Portugal

Corresponding Author: Ana Cristina da Silva Sousa, Department of Dermatology, Centro Hospitalar Vila Nova de Gaia/Espinho, Rua Conceição Fernandes, 4434-502 Vila Nova de Gaia, Portugal, Tel: 351-916568715, Email: a.cristina.silvasousa@gmail.com

Abstract Bullous lupus erythematosus is a rare clinical form of lupus. The diagnosis is challenging and involves the exclusion of other subepidermal bullous dermatoses. We present a 21-year-old woman with erythematosus, polycyclic plaques with vesiculobullae along the periphery, creating an erythema gyratum repens-like pattern on acral regions. The cutaneous biopsy, analytical, and autoimmune studies support the diagnosis of systemic lupus erythematosus. Dapsone and glucocorticosteroids were given with prompt resolution of the lesions within two weeks. To our knowledge this is the first case of bullous lupus erythematosus with this atypical acral presentation.

Keywords: bullous lupus erythematosus, erythema gyratum repens-like pattern, systemic lupus erythematosus

Introduction

Bullous lupus erythematosus (BLE) is a rare condition, characterized by a subepidermal vesicobullous eruption, typically associated with other manifestations of systemic lupus erythematosus (SLE) [1]. Erythema gyratum repens (EGR) is a rare disorder, characterized by a concentric, serpiginous migrating erythema with some fine leading scale, creating a wood grain pattern. Most of the cases reported an association with underlying malignancy, although there are case reports related to benign diseases [2, 3]. "Lupus erythematosus gyratus repens" is interpreted clinically and

histologically as an annular variant of subacute cutaneous lupus erythematosus and was described in 1975 by Helwitt et al. [4].

Case Synopsis

We present a 21-year-old, previously healthy woman, referred to our department owing to a three-day history of cutaneous lesions, particularly on acral regions. She denied any drug ingestion in the past month. On physical examination we observed erythematosus polycyclic and annular plaques with vesicles and tense blisters on the periphery, most of them with a wood grain pattern (**Figures 1-3**). The patient complained of asthenia, arthralgia, as well as Raynaud phenomenon symptoms. A skin biopsy was performed, which revealed a subepidermal blister with extensive inflammatory infiltrate of polymorphonuclear cells (**Figure 4**). Direct immunofluorescence showed a granular deposition of IgG and IgM at the dermo-epidermal junction. Autoimmune serology showed a positive antinuclear antibody >1/1280 with speckled pattern, anti-double-stranded DNA antibody 1/80, anti-Smith antibody 33.30 U/ml, anti-ribonucleoprotein antibody 114.00 U/ml, and anti-Ro 20.70 U/mL. Laboratory analysis revealed: lymphopenia, low serum C3 and C4 (33.5 and 1.8mg/dL respectively), erythrocyte sedimentation rate 69mm/hr, proteinuria, leukocyturia, and erythrocyturia in the urine analysis. She was observed by consultants in

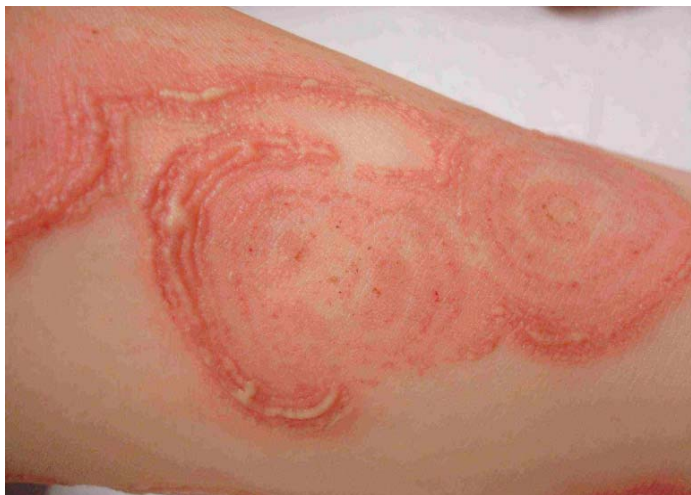

Figure 1. Polycyclic and annular plaques with vesicles on the periphery creating a wood grain pattern in the leg.

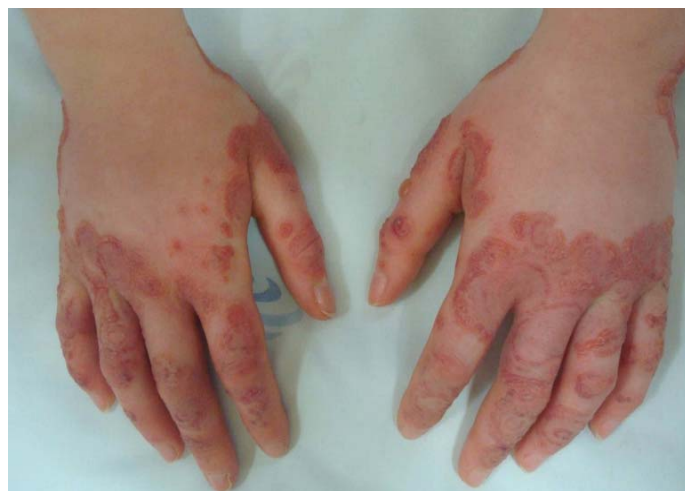

Figure 2. Erythematous plaques with vesicles and tense blisters on both hands

rheumatology and nephrology who confirmed the involvement of more than two joints and lupus nephritis. Screening for malignancies was negative. With all this data the diagnosis of systemic lupus erythematosus with an erythema gyratum repens-like pattern of cutaneous bullous lupus was made.

A glucose 6-phosphate dehydrogenase deficiency was excluded and dapsone 100mg daily with 10mg of prednisone was given with rapid improvement of the lesions with complete resolution in two weeks (**Figure 5**).

Case Discussion

Bullous lupus erythematosus is a rare disease, with female predominance; it typically begins between

the second and fourth decade of life. It is characterized by an abrupt onset of tense vesiculobullae, mainly with a photodistributed pattern. Uncommonly the mucous membrane and photoprotected skin are involved. These lesions usually heal without scarring [1, 5]. Patients usually have other constitutional symptoms of SLE, like fever, fatigue, arthralgia, and weight loss. There are some case reports that correlate the appearance of BLE with lupus nephritis [6, 7].

In our patient the lesions appeared in parallel with constitutional symptoms and it was possible to make the diagnosis of SLE by clinical manifestations and laboratory testing.

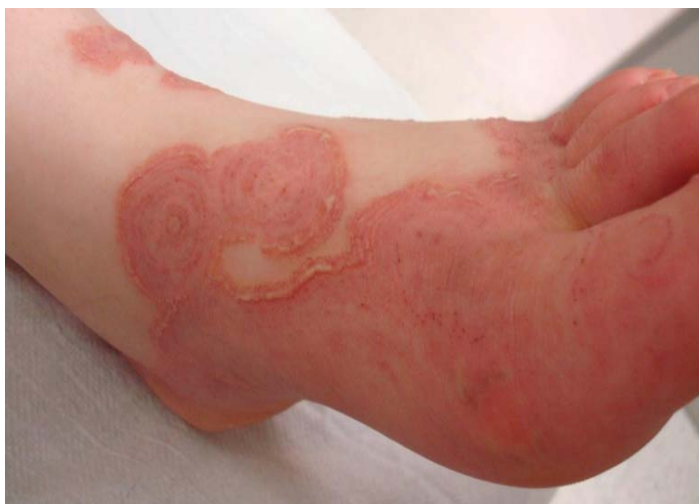

Figure 3. Cutaneous lesions on the foot with an erythema gyratum repens-like pattern

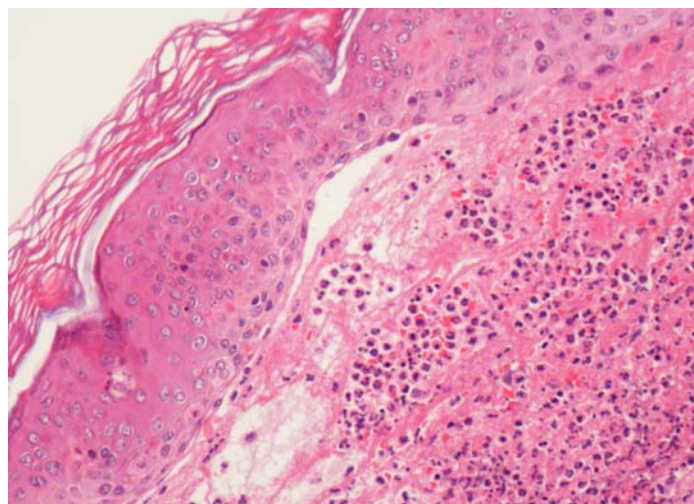


Figure 4. Subepidermal blister filled with erythrocytes and numerous neutrophils. H&E, 200x.

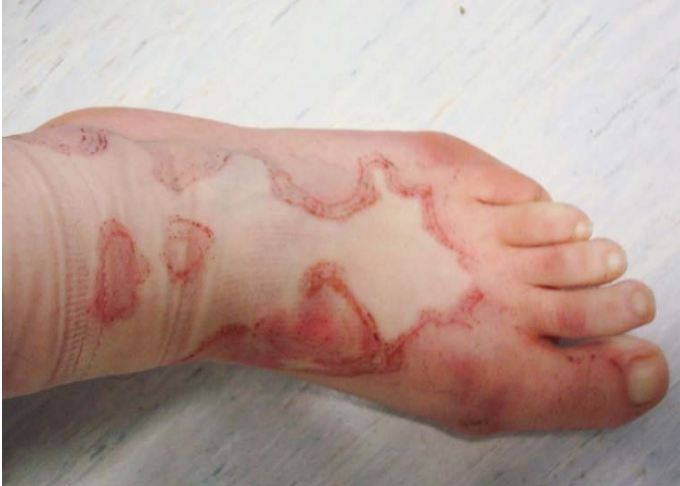

Figure 5. Postinflammatory patch after one week of dapsone.

The histopathology of BLE is described as showing subepidermal bullae with a dermal inflammatory infiltration that is mainly composed of neutrophils, sometimes leading to neutrophilic microabscesses in the papillary dermis, a pattern similar to dermatitis herpetiform [8, 9]. Direct immunofluorescence shows a granular and/or linear deposition of IgG; sometimes IgA, IgM, and complement components are also observed at the dermal-epidermal junction [9]. Most patients have a positive anti-nuclear antibody and commonly, anti-double stranded DNA and anti-collagen type VII [10]. Dapsone is the first-line treatment that generally produces cessation of new blister formation and complete resolution of the dermatosis within days, frequently leaving postinflammatory hypopigmentation or hyperpigmentation [5, 9]. Typically, there is minimal response with corticosteroids and other immunosuppressive drugs [5, 11]. Our patient met the 2012 Systemic Lupus International Collaboration

criteria for the diagnosis of SLE and had clinical and immunohistopathology evidence of bullous lupus in an EGR pattern, with a complete response to dapsone.

Erythema gyratum repens is a rare disease with a pathognomonic appearance but a nonspecific histology. Mild parakeratosis and perivascular lymphocytic infiltrates in the superficial dermis are described [3]. Most of the cases report an association with malignancy, but there are reports of psoriasis, limited systemic sclerosis, and lepromatous leprosy with an EGR pattern presentation [2, 3, 12]. Also, there is an entity known as "Lupus erythematosus gyratus repens" described by Helwitt et al. [4]. The lesions are widespread, concentric, erythematous plaques, often with double-counter edges; it is histologically interpreted as an annular variant of subacute cutaneous lupus erythematosus [4, 13].

There are few previous reports on this issue. One showed infiltrated erythematous plaques with EGR in a patient with SLE [14]. Another report describes a patient with SLE and leukocytoclastic vasculitis clinically mimicking EGR [15]. Similarly, to our case, there is one case in which the patient developed bullous lupus with an EGR pattern, but the lesion presentation and localization were quite different [16].

Conclusion

Our patient is interesting because her findings combine the histological predominance of neutrophils with the presence of blisters arranged in an EGR pattern, an atypical form of cutaneous lupus.

References

1. Contestable JJ, Edhegard KD, Meyerle JH. Bullous systemic lupus erythematosus: a review and update to diagnosis and treatment. *Am J Clin Dermatol* 2014; 15: 517–24. [PMID: 25358414].
2. Galán-Gutiérrez M, Martínez-Peinado CM, Ruiz-Villaverde R. Erythema gyratum repens: Not always a paraneoplastic disease. *Rev Clin Esp*. 2014 Oct;214(7):425-7. [PMID: 24954293].
3. Rongioletti F, Fausti V, Parodi A. Erythema gyratum repens is not an obligate paraneoplastic disease: a systematic review of the literature and personal experience. *J Eur Acad Dermatol Venereol*. 2014 Jan;28(1):112-5. [PMID: 22830929].
4. Helwitt J, Benveniste M, Kaufmann P, Lessana-Leibowitch M. Les éruptions figurées centrifuges au cours du lupus érythémateux: a propos d'un cas de lupus érythémateux gyratum repens. *Ann Dermatol Syph* 1975; 102: 481–9. [PMID: 1231629].
5. Yung A, Oakley A: Bullous systemic lupus erythematosus. *Australas J Dermatol* 41: 234-7 (2000). [PMID: 11105368].
6. Ng YY, Chang T, Chen TW, Liou HN, Yang AH, Yang WC. Concomitant lupus nephritis and bullous eruption in systemic lupus erythematosus. *Nephrol Dial Transplant* 14: 1739-43(1999). [PMID: 10435885].

7. Momen T, Madihi Y. Bullous Systemic Lupus Erythematosus and Lupus Nephritis in a Young Girl. *Oman Med J*. 2016 Nov;31(6):453-5. [PMID: 27974963].
8. Burrows NP, Bhogal BS, Black MM, Rustin MH, Ishida-Yamamoto A, Kirtschig G, Russel Jones R. Bullous eruption of systemic lupus erythematosus: a clinicopathological study of four cases. *Br J Dermatol* 128: 332-8 (1993). [PMID: 8471519].
9. Vassileva S. Bullous systemic lupus erythematosus. *Clin Dermatol*. 2004; 22:129-38. [PMID: 15234014].
10. Chan LS, Lapiere JC, Chen M, Traczyk T, Mancini AJ, Paller AS, Woodley DT, Marinkovich MP. Bullous systemic lupus erythematosus with autoantibodies recognizing multiple skin basement membrane components, bullous pemphigoid antigen 1, laminin-5, laminin-6, and type VII collagen. *Arch Dermatol*. 1999; 135:569-73. [PMID: 10328198].
11. Duan L, Chen L, Zhong S, Wang Y, Huang Y, He Y, Chen J, Shi G. Treatment of Bullous Systemic Lupus Erythematosus. *J Immunol Res*. 2015; 2015:167064. [PMID: 26090480].
12. Mohanan S, Devi AS, Kumari R, Thappa DM, Ganesh RN. Novel presentation of lepromatous leprosy in an erythema gyratum repens-like pattern. *Int J Dermatol*. 2014;53:210-2 [PMID: 24320626].
13. Kreft B, Marsch WC. Lupus erythematosus gyratus repens. *Eur J Dermatol*. 2007;17:79-82. [PMID: 17324834].
14. Khan Durani B, Andrassy K, Hartschuh W. Neutrophilic dermatosis with an erythema gyratum repens-like pattern in systemic lupus erythematosus. *Acta Derm Venereol*. 2005;85: 455-6. [PMID: 16159745].
15. Pique E, Palacios S, Santana Z. Leukocytoclastic vasculitis presenting as an erythema gyratum repenslike eruption on a patient with systemic lupus erythematosus. *J Am Acad Dermatol*. 2002;47:S254-6. [PMID: 12399742].
16. Fruchter R, Shaikh G, Myers KL, Eungdamrong NJ, Lee HS, Franks AG Jr. An erythema gyratum repens variant of bullous lupus erythematosus. *JAAD Case Rep*. 2016 Mar 3;2(2):111-3. [PMID: 27051846].