

# UC Davis

## Dermatology Online Journal

### Title

Langerhans cell histiocytosis with nail changes and multisystem disease: a case report

### Permalink

<https://escholarship.org/uc/item/0n60013n>

### Journal

Dermatology Online Journal, 22(7)

### Authors

de Jesus Semblano Bittencourt, Maraya  
Moraes Dias, Carolina  
Lima Lage, Thaiané  
et al.

### Publication Date

2016

### DOI

10.5070/D3227031651

### Copyright Information

Copyright 2016 by the author(s). This work is made available under the terms of a Creative Commons Attribution-NonCommercial-NoDerivatives License, available at <https://creativecommons.org/licenses/by-nc-nd/4.0/>

Peer reviewed

## Case Presentation

**Langerhans cell histiocytosis with nail changes and multisystem disease: a case report.**

**Maraya de Jesus Semblano Bittencourt, Carolina Moraes Dias, Thaiane Lima Lage, Amanda Magno Parijós, Letícia Brito Mesquita, Alessandra Haber Carvalho**

**Dermatology Online Journal 22 (7): 14**

**Dermatology department of Federal University of Pará, Brasil**

## Correspondence:

Maraya de Jesus Semblano Bittencourt  
Email: marayabittencourt@hotmail.com

---

## Abstract

Nail involvement in Langerhans cell histiocytosis is uncommon and is said to indicate a poor prognosis. We describe a 2-year-old boy with onycholysis, subungual hyperkeratosis, and hemorrhages on his fingernails. He also had hepatosplenomegaly and pulmonary involvement. The diagnosis of Langerhans cell histiocytosis was made by histopathologic examination of skin and liver.

The role of nail involvement as an unfavorable prognostic sign is still unclear and this paper concludes that nail involvement in Langerhans cell histiocytosis is a possible sign of multisystemic involvement.

**Keywords: histiocytosis, Langerhans cell, nail diseases**

## Introduction

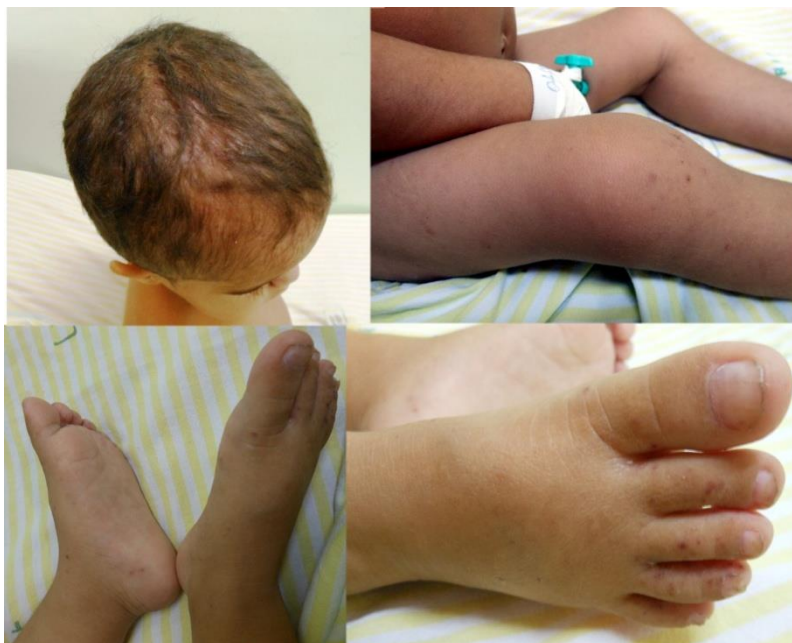Langerhans cell histiocytosis (LCH) is a rare disease characterized by proliferation and accumulation of clonal dendritic cells (LCH cells) bearing an immunophenotype very close to that of the normal epidermal Langerhans cells of the skin. LCH may present itself in a variety of clinical forms ranging from the spontaneous regression of the single bone lesion called **eosinophilic granulomas** to a severe multisystemic disorder called Letterer-Siwe disease. Diagnosis is made in a presumptive manner when the typical morphological features of Langerhans cells are observed through optical microscopy; positive immunohistochemical assays for S100 protein and CD1a are helpful. Electron microscopy can also be confirmatory.

Multi-organ LCH manifests with visceral organ involvement (lung, liver, spleen, gastrointestinal tract) or involvement of the hematopoietic system (pancytopenia), with or without bone lesions. In the worst case scenario the lung (tachypnea, large bullae, spontaneous pneumothorax), liver (hepatomegaly, ascites), or hematopoietic system show signs of organ dysfunction [1].

More than half of the patients younger than 2 years with disseminated LCH and organ dysfunction die of the disease. The frequency is greater in males than in females, with a male-to-female ratio of 2:1. Nail involvement in Langerhans cell histiocytosis is uncommon and is said to indicate a poor prognosis. We describe a 2-year-old boy with onycholysis, subungual hyperkeratosis, and hemorrhages of fingernails associated with multisystemic disease.

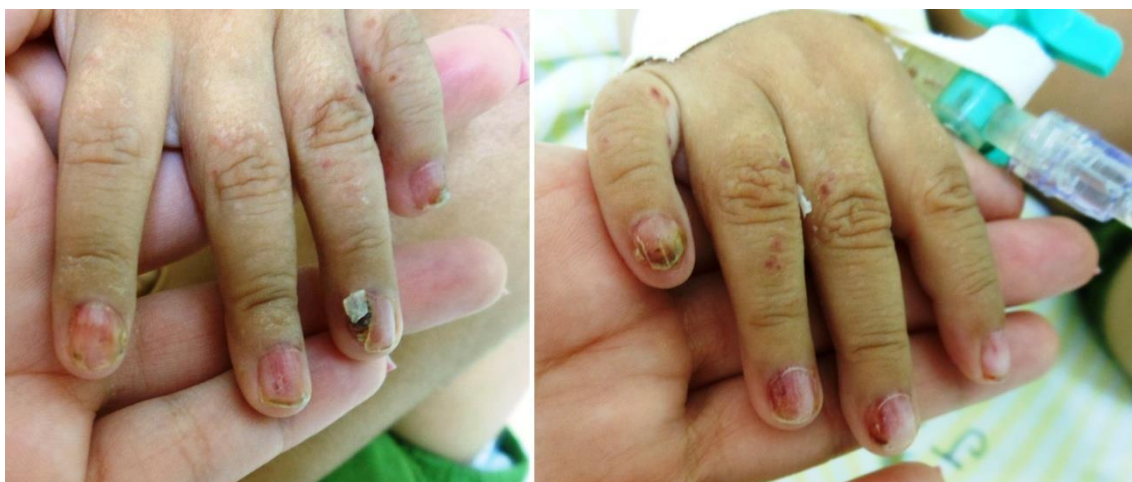## Case synopsis

A 2-year-old boy presented with a 1-month history of asymptomatic changes in most of the fingernails, fever, weight loss, and fatigue. Cutaneous examination revealed yellowish greasy scales and crusts over the scalp and a small number of purpuric papules over the trunk, feet, arms, and legs (Figure 1).



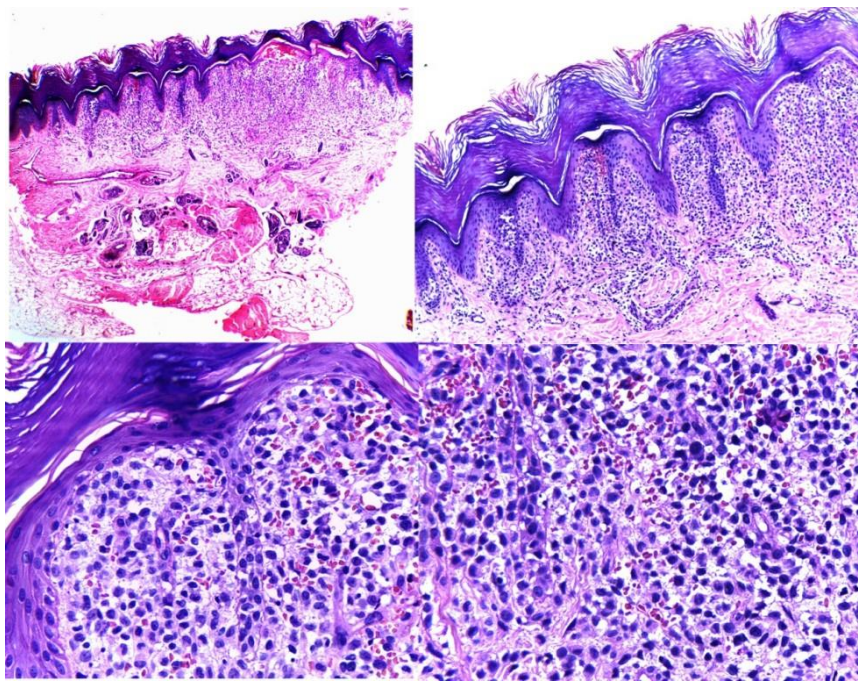
**Figure 1.** Cutaneous examination revealed yellowish greasy scales and crusts over the scalp and small number of purpuric papules over the trunk, feet, arms and legs

His fingernails showed onycholysis, subungual hyperkeratosis, and hemorrhages (Figure 2).



**Figure 2.** Fingernails with onycholysis, subungual hyperkeratosis and hemorrhages

He had also hepatosplenomegaly, ascites, and tachypnea. Laboratory studies showed elevation in liver enzymes. Histologic examination of skin revealed a diffuse infiltrate in the upper dermis composed of large mononuclear cells with reniform nuclei and abundant eosinophilic cytoplasm (Figure 3).



**Figure 3.** Histologic examination of skin revealed a diffuse infiltrate in the upper dermis composed of large mononuclear cells with reniform nuclei and abundant eosinophilic cytoplasm. Immunohistochemical studies showed intense cytoplasmic positivity for CD1a surface antigen and S-100 protein.

Immunohistochemical studies showed intense cytoplasmic positivity for CD1a surface antigen and S-100 protein, which confirmed the diagnosis of LCH. The same histologic aspect was observed in the liver biopsy. High-resolution computed tomography of the chest showed a combination of nodules and cavitated nodules in both lungs. Abdominal ultrasonography showed a hyperechoic heterogeneous liver. Myelogram and investigation of bone involvement was normal. After the diagnosis he was referred to an oncology center and was lost to follow up.

## Discussion

The severity of LCH tends to be age-related, with extensive multi-system LCH with or without organ failure seen mostly in the very young. Multifocal restricted single-system LCH is often diagnosed in children between 2 and 5 years [1]. Cutaneous lesions are the most common presenting sign and the eruption may be extensive, involving the scalp, face, trunk, and buttocks as well as the intertriginous areas. The individual cutaneous lesions are typically purpuric and scaly. Nail changes in Langerhans cell histiocytosis are well documented, distinctly uncommon, and can be the first clinical symptom of the disease [2].

Nail involvement manifests as longitudinal grooving, purpuric striae, subungual hyperkeratosis, onycholysis, nail dystrophy, loss of nail plate, and paronychia [2-9]. These changes in LCH are said to indicate a poor prognosis and mostly occur in patients with multisystem disease and involvement of high-risk organs, such as the liver, the spleen, the lungs, or the hematopoietic system, involvement which is known to be significantly related to mortality [1-4]. Pulmonary LCH is most often seen in the third or fourth decade of life but can also be part of multi-system LCH in the young child with nail involvement [5], as in our case.

Harper & Staughton (1983) described a patient with fulminating histiocytosis X and nail lesions who died despite therapy [6]. A review by Timpatanapong et al. (1984) of 15 cases of LCH showed that three of the seven patients with Letterer-Siwe disease had nail involvement and all three died rapidly. The authors conclude that nail involvement in histiocytosis X is an unfavorable prognostic sign [3]. In contrast, in the scarce published cases in which nail changes were not associated with multisystem disease, the response to chemotherapy was excellent [4,7]. Valdivieso & Bueno [8] have suggested that nail changes in LCH may be underdiagnosed, because sometimes nail involvement may be attributed to the habit of nail biting. The histology of specific nail unit lesions is similar to that of cutaneous lesions comprising typical Langerhans cells [2,9].

There are insufficient data to draw definite conclusions as to whether nail involvement in LCH is an independent prognostic factor of poor outcome. In summary, the case reported here illustrates that nail changes can be associated with multisystem involvement.

## References

1. Egeler RM, van Halteren AG, Hogendoorn PC, Laman JD, Leenen PJ. Langerhans cell histiocytosis: fascinating dynamics of the dendritic cell-macrophage lineage. *Immunol Rev.* 2010; 234(1):213-32. PMID: 20193021.

2. Mataix J, Betlloch I, Costa AL, Crespo MP, Guilleme CM. Nail changes in Langerhans cell histiocytosis: a possible marker of multisystem disease. *Pediatr Dermatol*. 2008; 25 (2): 247-51. PMID: 18429791.
3. Timpatanapong P, Hathirat P, Isarangkura P. Nail involvement in histiocytosis X. A 12-year retrospective study. *Arch Dermatol* 1984; 120(8):1052-6. PMID: 6235781.
4. Ellis JP. Histiocytosis X unusual presentation with nail involvement. *J R Soc Med*. 1985; 78(11):3-5. PMID: 3879285.
5. Chander R, Jaykar K, Varghese B, Garg T, Seth A, Nagia A. Pulmonary disease with striking nail involvement in a child. *Pediatr Dermatol*. 2008; 25(6):633-4. PMID: 19067872.
6. Harper JJ, Staughton R. Letterer-Siwe disease with nail involvement. *Cutis*. 1983; 31(5):493, 498. PMID: 6851645.
7. Jain S, Sehgal VN, Bajaj P. Nail changes in Langerhans cell histiocytosis. *J Eur Acad Dermatol Venereol* 2000;14(3):212-5. PMID: 11032069.
8. Valdivieso M, Bueno C. Langerhans cell histiocytosis. *Actas Dermosifiliogr* 2005; 96:275-84. PMID: 16476387.
9. Holzberg M, Wade TR, Buchanan ID, Spraker MK. Nail pathology in histiocytosis X. *J Am Acad Dermatol* 1985; 13(3):522-4. PMID: 3877083.