

Letter

Delay in diagnosis of acral melanoma

Roberto Rheingantz da Cunha Filho, Leandra Matte, Ricardo Hohmann Camina

Dermatology Online Journal 22 (10): 19

School of Medical Sciences, Universidade do Oeste de Santa Catarina (UNOESC), Joaçaba, Santa Catarina, Brazil

Correspondence:

Roberto Rheingantz da Cunha Filho
Email: robertodermatologista@yahoo.com.br

Abstract

We report a 41-year-old woman presented with a 4-year history of an exuberant, erythematous tumor, with necrotic appearance of the right distal toe. The histopathology examination showed a nodular-ulcerative melanoma, with bone infiltration. Widespread metastases including the right ovary, peritoneum, and right breast were present. The patient was misdiagnosed for almost 4 years as having onychomycosis, ingrown nail and pyogenic granuloma.

Keywords: melanoma; nail diseases; diagnosis

Introduction

Malignant melanoma is a major public health problem, which has increased significantly in recent decades. Acral malignant melanoma (AMM) is an uncommon subtype seen in approximately 5% of cases. Malignant melanoma of the nail apparatus (MMNA) varies between 1% and 3% of cases, with a poor prognosis when compared to other types [1,2]. We present a patient with a markedly delayed diagnosis.

Case synopsis

A 41-year-old woman, phototype III, presented with a tumor of the right distal toe, measuring approximately 5 cm. The nail plate was missing owing to neoplastic destruction. The proximal portion of the tumor presented with a macular area with discreet dark-brown pigmentation - Hutchinson's sign (black arrow, Figure 1).

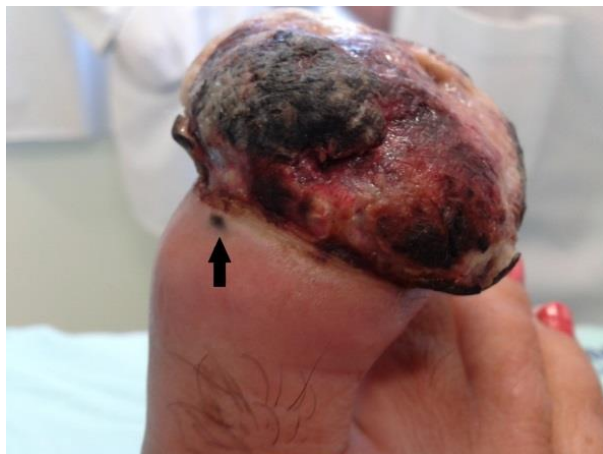

Figure 1. Necrotic tumor of great toe measuring approximately 5 cm. Proximal portion shows Hutchinson sign (black arrow).

The patient complained of localized pain and swelling in the foot and denied any family history of melanoma or other current diseases. There were no palpable inguinal nodes. Four years ago, the medical history revealed a small dark macule of the subungual region and borders. The physician prescribed antifungal treatment for two years, with no response. The tumor evolved into a small erythematous nodule at the nail edge. An incisional biopsy was performed and revealed malignant melanoma (MM). The toe was amputated. The examination showed an ulcerated, nodular MM (Figure 2), with small cells exhibiting basophilic nuclei and scarce cytoplasm.

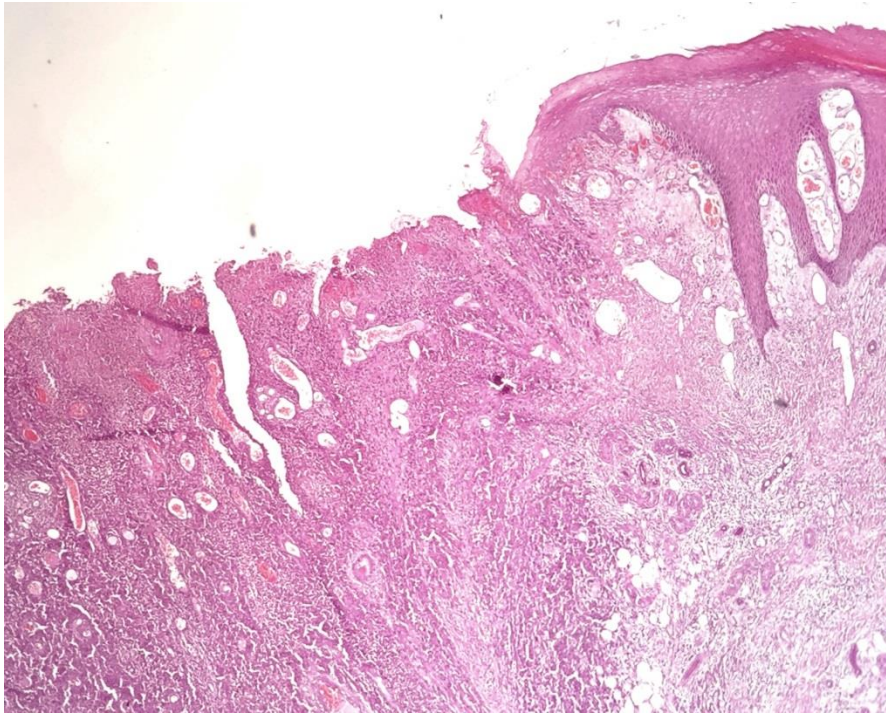


Figure 2. Histopathology showing ulcerated nodular melanoma H&E 40x

High cellularity and frequent mitotic figures (arrow, up to 14 mitoses/mm²) were also seen (Figure 3). The tumor infiltrated bone and measured approximately 5.5cm wide and 1.5cm thick. There was no evidence of angio-lymphatic invasion. Focal perineural invasion was observed. Tumor-free surgical margins were obtained.

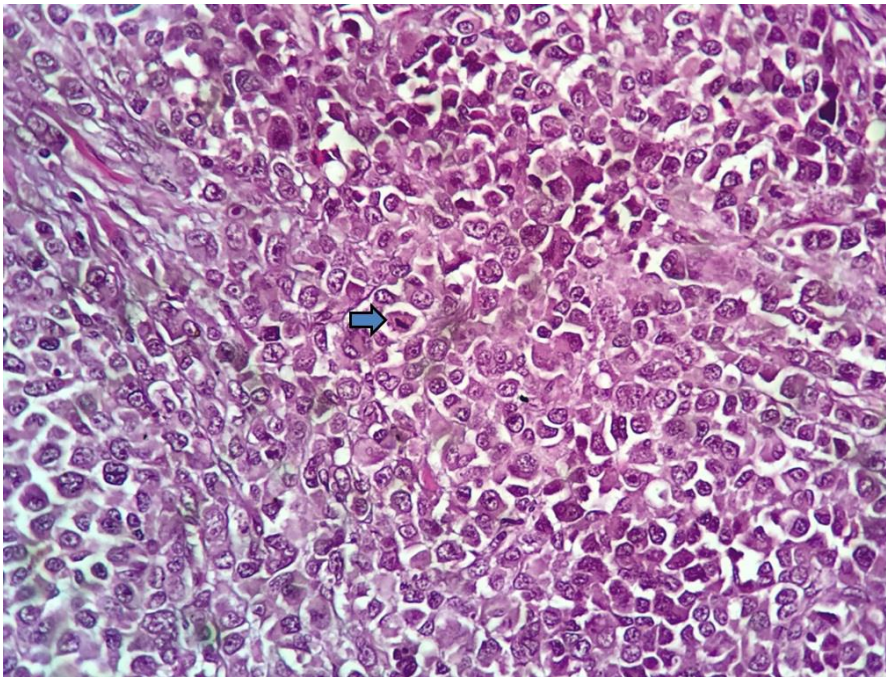


Figure 3. Tumor cells showing basophilic nuclei and scarce cytoplasm, with mitotic figures up to 14 mitoses/mm². H&E 400x.

The computed tomography (CT) scan of pelvis, abdomen and chest were normal. Lactate dehydrogenase (LDH), alkaline phosphatase (AP), bilirubin, and transaminases levels were normal.

Three months after resection of the lesion, the patient's pelvic volume increased. Another CT scan was performed, showing a pelvic mass and subcutaneous lesion in the right breast and chest wall. Involved retroperitoneal lymph nodes in the celiac trunk were found. The pelvic lesions and right breast were resected and histological examination showed metastatic melanoma.

Discussion

AMM and MMNA are often neglected by many physicians and patients, especially in the early stages. This is probably because they are unusual and may be mistaken for other skin diseases of infectious or inflammatory origin and by benign neoplasms. There is no consensus, and there is an estimate that one-third to two-thirds of cases are misdiagnosed initially as warts, trauma, ingrown nail, among others [1, 2, 3, 4]. AMM can manifest itself in different ways, but it is typically an asymmetric, brown or black pigmentation with irregular borders. It may present as longitudinal melanonychia in the nail matrix. However, the pigmentation is not always easily evident and there may be amelanotic cases, which can make clinical diagnosis difficult [1, 5]. Our patient's melanoma had amelanotic characteristics, which may have contributed to being initially identified as granuloma pyogenicum. However, a detailed clinical examination showed a small area of pigmentation in the proximal border (Figure 1, Black Arrow). It was also initially misdiagnosed as fungal disease.

Conclusion

Avoiding delay in diagnosis of the acral sites requires a high index of suspicion and willingness to perform adequate biopsies in these sensitive sites.

References

1. Bologna JL, Jorizzo JL, Schaffer JV. *Dermatology*. 3rd ed. Philadelphia: Elsevier Saunders; 2012. Vol 2. pp 1885-1910.
2. Metzger S et al. Extent and consequences of physician delay in the diagnosis of acral melanoma. *Melanoma Res* 1998;8:181-6. [PMID: 9610874]
3. Phan S et al. Acral lentiginous melanoma: histopathological prognostic features of 121 cases. *Br J Dermatol* 2007 157, pp 311–318. [PMID: 17596173]
4. Amel EJ et al. A misdiagnosed bed melanoma. *Dermatol Online J* 2010;16;13. [PMID: 20673541]
5. Jennifer R. Stalkup, BA, Ida F. Orengo, MD, and Rajani Katta, *Controversies in Acral Lentiginous Melanoma*. *Dermatol Surg* 2002;28:1051–1059.
6. Bormann G, Marsch WC, Haerting J, Helmbold P. Concomitant traumas influence prognosis in melanomas of the nail apparatus. *Br J Dermatol* 2006 155, pp76–80. [PMID: 16792755]
7. Phan A. Acral lentiginous melanoma: a clinicoprognostic study of 126 cases. *Br J Dermatol* 2006;155:561-9. [PMID: 16911282]
8. Jeon Sy et al. Long-term survival analysis and clinical follow-up in acral lentiginous malignant melanoma undergoing sentinel lymph node biopsy in Korean patients. *Ann Dermatol* 2014;26:177-83. [PMID: 24882971]
9. Gumaste et al. Analysis of Recurrence Patterns in Acral versus Non-Acral Melanoma: Should Histologic Subtype Influence Treatment Guidelines? *J Natl Compr Canc Netw*. 2014;12:1706–1712. [PMID: 25505211]