

White fibrous papulosis of the neck

Carmen Castilla, MD, Randie H. Kim, MD PhD, Shane A. Meehan, MD, Rhonda Pomerantz, MD

Ronald O. Perelman Department of Dermatology, NYU School of Medicine, NYU Langone Medical Center

Abstract

White fibrous papulosis of the neck is a rare diagnosis that typically presents with white, 2-to-3-mm papules on the posterior aspect of the neck. We present an elderly woman with diffuse involvement on her abdomen and back.

Case Presentation

PATIENT: Elderly woman

DURATION: Nine years

DISTRIBUTION: Neck and trunk

HISTORY: An elderly Hispanic woman presented to a New York University affiliated dermatologist with the new onset of skin-colored papules. The papules first appeared on her neck, and over time the papules spread to her back and abdomen. Past medical history was non-contributory. She denied new medications and any systemic symptoms. She had no personal or family history of rheumatologic disease or a family history of similar skin conditions. She was treated with mild-to-high-potency topical glucocorticoids, tazarotene cream, and tacrolimus ointment without improvement.

PHYSICAL EXAMINATION: Numerous, skin-colored-to-slightly-white, 2-to-3-mm papules were scattered on the posterior aspect of the neck, abdomen, and central portion of the upper back (**Figure 1**).

LABORATORY DATA: A complete blood count, a blood chemistry profile, and liver function tests were normal.

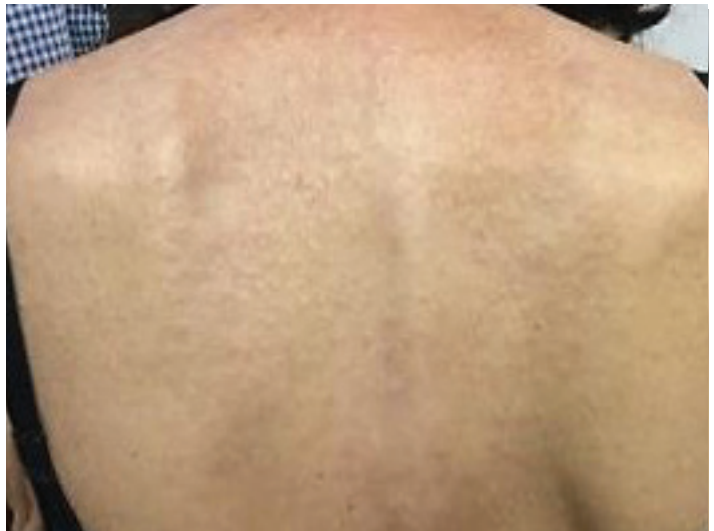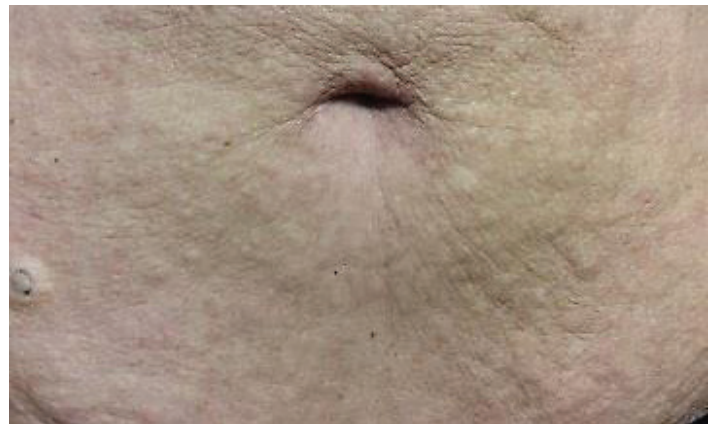

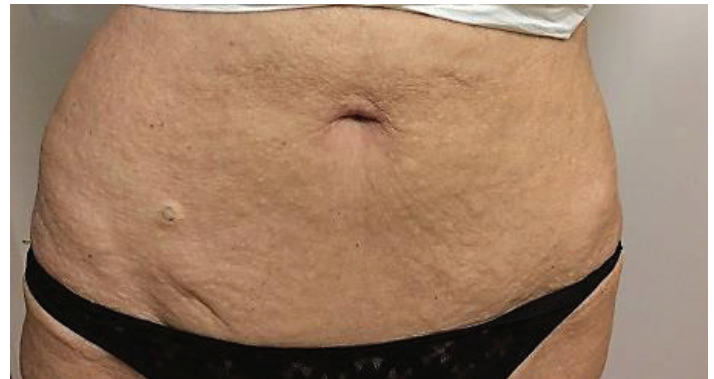
Figure 1. Numerous, skin-colored-to-slightly-white, 2-to-3-mm papules were scattered on the posterior aspect of the neck, abdomen, and central portion of the upper back.

HISTOPATHOLOGY: Within the mid-dermis, there are thickened collagen bundles. The overlying epidermis is unremarkable (**Figure 2**).

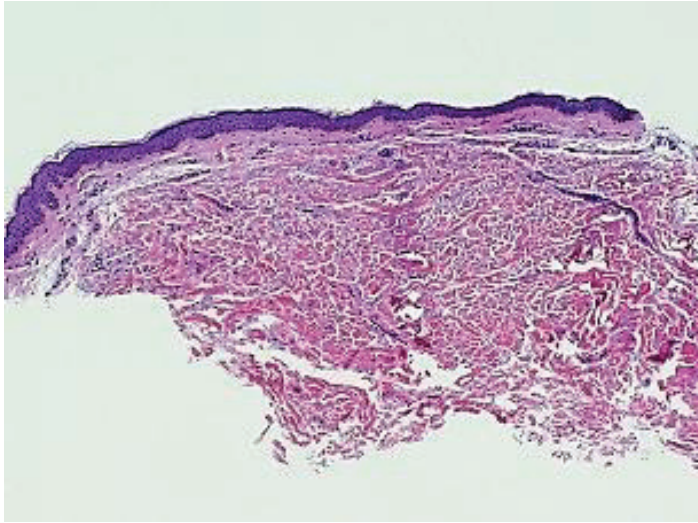


Figure 2. Within the mid-dermis, there are thickened collagen bundles. The overlying epidermis is unremarkable.

DIAGNOSIS: White fibrous papulosis of the neck

Discussion

White fibrous papulosis of the neck (WFPN) is a rare disease that typically presents in middle-aged women or men [1]. WFPN typically appears as numerous, small, white, well-circumscribed, non-pedunculated, non-follicular papules on the posterior aspect of the neck [2-4]. Over time, the papules may increase in number. Involvement of areas besides the posterior aspect of the neck is rare although it has been reported [5-7]. Although the pathogenesis is not completely understood, it is thought to be due to intrinsic age-related alterations in the dermal collagen fibers. There is no obvious ethnic predisposition, with cases reported in Caucasian, Middle Eastern, Asian, and Hispanic patients [3,8-13].

Histopathologic examination shows thick, variably-sized collagen fibrils in the papillary to mid-dermis [2]. The elastic fibers remain structurally normal but may be decreased in number. To date, no associated systemic co-morbidities have been reported in WFPN.

Fibroelastolytic papulosis of the neck (FEPN) is a distinct diagnosis with histopathologic features

that are similar to both WFPN and pseudoxanthoma elasticum (PXE). This entity presents on flexural regions with yellow papules that may coalesce into cobblestoned-appearing plaques. Histopathologic features include dermal papillary elastosis with papillary dermal melanophages [14]. FEPN also is thought to be secondary to intrinsic, age-related changes. FEPN and WFPN may be distinguished through clinical features as well as differences in the involved collagen-to-elastic-fiber ratios.

WFPN has no known effective treatments and does not spontaneously regress. Fractionated carbon-dioxide laser treatment of FEPN has been described with improvement in cosmetic appearance [15]. Due to the similar histopathologic findings between WFPN and FEPN, laser may be a reasonable consideration for treatment of WFPN. Further studies for the treatment of WFPN need to be performed.

References

1. Song YC, et al. A case of fibroelastolytic papulosis on the neck of a young man. *Ann Dermatol* 2011;23:193
2. Shimizu H, et al. White fibrous papulosis of the neck: review of our 16 cases. *Nippon Hifuka Gakkai Zasshi* 1985; 95: 1077
3. Shimizu H, et al. White fibrous papulosis of the neck: a new clinicopathologic entity? *J Am Acad Dermatol* 1989;20: 1073
4. Kim HS, et al. White fibrous papulosis of the neck. *J Eur Acad Dermatol Venereol* 2007; 21: 419
5. Vermersch-Langlin A, et al. White fibrous papulosis of the neck. *Int J Dermatol* 1993; 32: 442
6. Redondo P, et al. White fibrous papulosis of the neck. *Dermatology* 1993; 186: 238
7. Mitoma C, et al. White fibrous papulosis on the trunk and upper arms. *Int J Dermatol* 2013;52:337
8. Joshi RK, et al. White fibrous papulosis of the neck. *Br J Dermatol* 1992;127:295
9. Wang DG, et al. White fibrous papulosis of the neck: a Chinese case. *J Dermatol* 2005;32:497
10. Balus L, et al. Fibroelastolytic papulosis of the neck: a report of 20 cases. *Br J Dermatol* 1997;137:461
11. Siragusa M, et al. White fibrous papulosis of the neck in three Sicilian patients. *Australas J Dermatol* 1996;37:202
12. Kim HS, et al. White fibrous papulosis of the neck. *J Eur Acad Dermatol Venereol* 2007; 2:419
13. Moreira AP, et al. White fibrous papulosis of the neck: the first South American case. *Dermatol Online J* 2009; 15:15:9
14. Rongioletti F, et al. Fibroelastolytic patterns of intrinsic skin ageing: pseudoxanthoma-elasticum-like papillary dermal elastolysis and white fibrous papulosis of the neck. *Dermatology* 1995; 191: 19
15. Chong S, et al. Treatment of fibroelastolytic papulosis with fractionated carbon dioxide laser. *Cosmet Laser Ther* 2015;17:90