

# UC Davis

## Dermatology Online Journal

### Title

Histiocytoid Sweet syndrome treated with azathioprine: a case report

### Permalink

<https://escholarship.org/uc/item/0cg9m1h9>

### Journal

Dermatology Online Journal, 21(7)

### Authors

Miller, Jonathan  
Lee, Nicole  
Sami, Naveed

### Publication Date

2015

### DOI

10.5070/D3217028123

### Copyright Information

Copyright 2015 by the author(s). This work is made available under the terms of a Creative Commons Attribution-NonCommercial-NoDerivatives License, available at <https://creativecommons.org/licenses/by-nc-nd/4.0/>

Peer reviewed

## Case presentation

### Histiocytoid Sweet syndrome treated with azathioprine: a case report

Jonathan Miller BS<sup>1</sup>, Nicole Lee MD MPH<sup>2</sup>, and Naveed Sami MD<sup>2</sup>

Dermatology Online Journal 21 (7): 13

<sup>1</sup>Quillen College of Medicine, East Tennessee State University, Johnson City, TN

<sup>2</sup>Department of Dermatology, University of Alabama at Birmingham, Birmingham, AL

## Correspondence:

Naveed Sami, MD  
Associate Professor  
Department of Dermatology  
University of Alabama at Birmingham  
EFH 414, 1530 3rd Ave S, Birmingham, AL, 35294  
Office: (205) 934-5188 Fax: (205) 934-5766  
Email: nsami@uab.edu

---

## Abstract

Histiocytoid Sweet syndrome (HSS) is a rare histologic variation of Sweet syndrome (SS) predominantly exhibiting mononuclear histiocytoid cells instead of neutrophils. We report a 22-year-old woman with HSS, who, after minimal improvement with colchicine and dapsone, had significant improvement of her cutaneous eruption and systemic symptoms following empiric treatment with azathioprine. Since azathioprine has historically been known to cause SS, this case highlights a previously unreported treatment response for the histiocytoid variant.

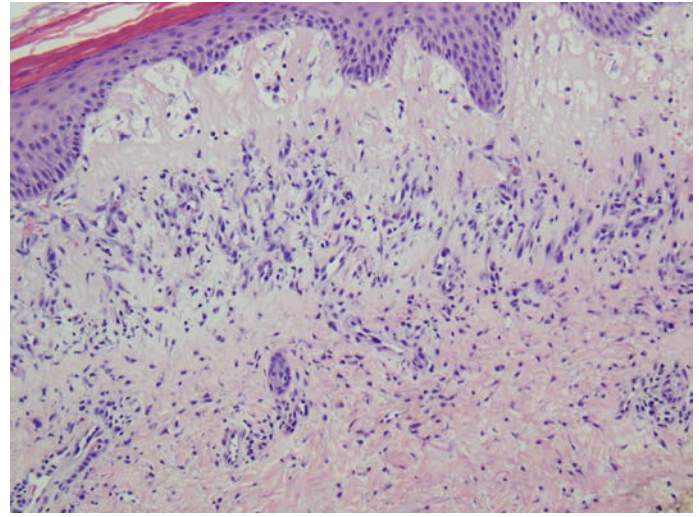
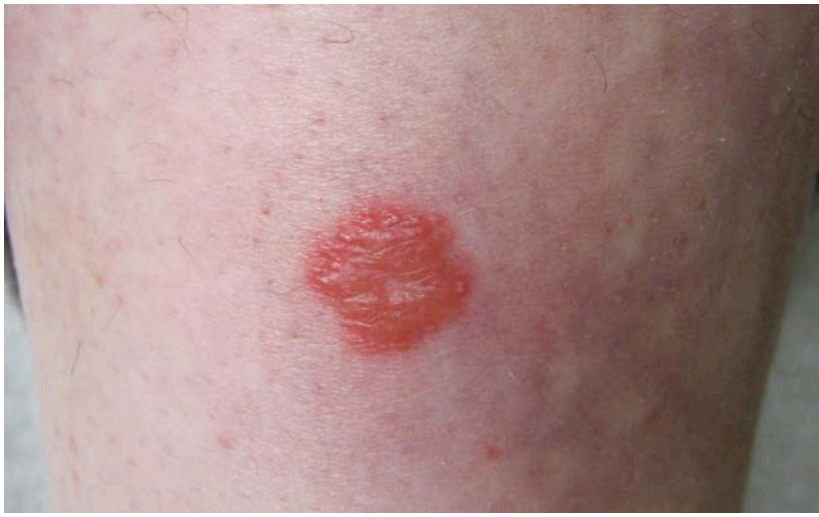**Keywords:** azathioprine, histiocytoid Sweet's syndrome, Sweet's syndrome, systemic therapy

## Introduction

Histiocytoid Sweet syndrome (HSS) is a rare variant of Sweet syndrome (SS), an acute febrile neutrophilic dermatosis. Although the cause of SS is unknown, various associations, including medications such as azathioprine, have been reported. We present a unique case of the histiocytoid variant that, improved with azathioprine.

## Case synopsis

A 22-year-old woman presented to the dermatology clinic for evaluation of a complex, six-year history of recurring discrete, non-pruritic, erythematous papules and plaques distributed sparsely on the extremities (Figure1). The patient had initially presented several years prior with orbital pseudotumor and a different skin rash that was diagnosed as leukocytoclastic vasculitis. In addition to systemic steroids, she was treated with mycophenolate mofetil (unable to tolerate due to gastrointestinal symptoms) and dapsone. At that time, there were no associated systemic findings; serologies were also negative for connective tissue disease (CTD).



**Figure 1.** Erythematous, well-demarcated papule on the pretibial region of the patient's right leg. **Figure 2.** The dermis is remarkable for edema and a superficial and deep perivascular interstitial mixed inflammatory infiltrate containing numerous histiocytes, lymphocytes and scattered mast cells and neutrophils (H&E, x40).

She presented four years later with the current cutaneous manifestation and symptoms of fatigue, myalgias, arthralgias, dyspnea, and migraines. She denied any new medications. A biopsy of the rash revealed prominent dermal edema, superficial and deep perivascular interstitial mixed inflammatory infiltrate containing numerous histiocytes (CD163 positive), lymphocytes, scattered mast cells (cKit positive), and neutrophils (myeloperoxidase positive) (Figure 2). All immunoperoxidase stains were performed with appropriately reactive controls. The patient also underwent an extensive evaluation for underlying diseases, including CTD, hematologic malignancies, and a pulmonary evaluation, all of which were negative. After correlation of clinicopathologic characteristics, a diagnosis of HSS was achieved.

The patient did not want to start systemic steroids owing to a previous experience of adverse effects from systemic steroids for an unrelated condition. Hence, the patient was initially treated separately with dapsone (150 mg/d) and colchicine (0.6 mg twice per day). However, both treatments provided minimal to no improvement of her cutaneous and systemic symptoms. Since she had a history of intolerance to mycophenolate mofetil, azathioprine (50mg daily) was started, after confirming a normal TPMT level (42.4; normal >21), which resulted in a significant improvement of her cutaneous lesions and systemic complaints.

Azathioprine was discontinued after six months of treatment when she developed recurrent upper respiratory tract infections. At that time, her HSS was under good control. After being off of the medication for one month, however, she developed a relapse of her initial systemic symptoms, along with one lesion on her foot. Control was reestablished after restarting azathioprine 50 mg/d, which she continues to tolerate well.

## Discussion

Histiocytoid Sweet syndrome (HSS) was first described ten years ago as a histopathologic variant of Sweet syndrome (SS) exhibiting histiocytic-appearing immature myeloid cells instead of neutrophils [1]. Recently, however, a clinicopathologic analysis of 12 HSS cases by Peroni et al. has deepened the histologic understanding of the cutaneous disorder by demonstrating that the immunohistochemical phenotype of the infiltrate is primarily that of M2-like CD163+ macrophages [2]. In addition, a recent systematic review of the literature by So et al. revealed that a total of 64 patients with HSS have been reported in the literature. Disease associations identified include autoimmune diseases, malignancies, infections and inflammation, inflammatory bowel disease, medications, and other conditions [3]. Despite a knowledge of HSS histology and associated conditions, however, the pathogenesis remains elusive.

Drug reactions in association with SS have been well cited in the literature. However, since HSS is a rare variant, drugs in association with classical SS are more widely known. In particular, azathioprine is a known culprit for inducing neutrophilic dermatosis [4], yet it has not been documented as a cause of HSS. This dissimilarity and clinical response in our patient could possibly relate to the effect of azathioprine reducing the number of immature myeloid cells, typically seen in HSS, by targeting the proliferation of lymphocytes through the inhibition of the de novo pathway for purine synthesis [5].

Conventional treatment for SS has been mainly corticosteroids (systemic and intralesional), including pulse therapy with methyl prednisolone. Chronic therapy with steroid sparing agents has been reported to consist of dapsone, potassium iodide, clofazimine,

and colchicine [6]. Although there are fewer reports describing therapy for the histiocytoid variant, successful treatment has been achieved with prednisolone, acetaminophen, aceclofenac, and dapsone [7].

## Conclusion

In conclusion, we have described a patient presenting with a histiocytoid variant of SS recalcitrant to multiple conventional treatments. The cutaneous and systemic symptoms improved with azathioprine in our patient. As a result, we offer that azathioprine may be considered as a possible alternative in the treatment of HSS.

## References

1. Requena L, Kutzner H, Palmedo G, Pascual M, Fernandez-Herrera J, Fraga J, Garcia-Diez A, Yus E. Histiocytoid Sweet syndrome: a dermal infiltration of immature neutrophilic granulocytes. *Arch Dermatol*. 2005;141(7):834-42. [PMID: 16027297]
2. Peroni A, Colato C, Schena D, Rongioletti F, Girolomoni G. Histiocytoid Sweet syndrome is infiltrated predominantly by M2-like macrophages. *J Am Acad Dermatol*. 2015 Jan;72(1):131-9. [PMID: 25440433]
3. So, JK, Carlos, CA, Frucht, CS, Cohen PR. Histiocytoid giant cellulitis-like Sweet's syndrome: case report and review of the literature. *Dermatol Online J*. 2015 Jan;21(3):4. [PMID: 25780979]
4. Grelle J, Halloush R, Khasawneh F. Azathioprine-induced acute febrile neutrophilic dermatosis (Sweet's syndrome). *BMJ Case Rep*. 2013 Aug 16;2013. [PMID: 23955987]
5. Taylor A, Watson C, Bradley J. Immunosuppressive agents in solid organ transplantation: Mechanisms of action and therapeutic efficacy. *Crit Rev Oncol Hematol*. 2005;56(1):23-46. [PMID: 16039869]
6. Limdiwala PG, Parikh SJ, Sha JS. Sweet's syndrome. *Indian J Dent Res*. 2014;25:401-5. [PMID: 25099003]
7. Bilgili SG, Karadag AS, Calka O, Bulut G. Histiocytoid Sweet syndrome. *Int J Dermatol*. 2014;53(2):80-2. [PMID: 23330976]