

Pyoderma gangrenosum associated with pseudo-Pelger-Huët anomaly in a patient with idiopathic myelofibrosis

Antonio Furci¹, Manfredo Bruni¹, Davide Geat¹, Chiara Colato², Giampiero Girolomoni¹, Donatella Schena¹

Affiliations: ¹Department of Medicine, Section of Dermatology, University of Verona, Verona, Italy; ²Section of Pathology, Department of Diagnostics and Public Health, University of Verona, Verona, Italy

Corresponding Author: Davide Geat, Piazzale Stefani 1, 37126 Verona, Italy, Tel: 39-045-8122547, Email: davidegeat@outlook.it

Abstract

Pseudo-Pelger-Huët anomaly is a condition in which almost all the granulocytes are hyposegmented and/or hypogranulated. It is typically recognized in peripheral blood smears and represents a marker of several disorders, such as myeloproliferative diseases and myelodysplasia. The occurrence of the pseudo-Pelger-Huët anomaly in the cutaneous infiltrate of pyoderma gangrenosum is very rare. We describe the case of a 70-year-old man with idiopathic myelofibrosis who developed pyoderma gangrenosum. Histological examination showed an infiltrate consisting of granulocytic elements with features of dysmaturity and segmentation anomalies (hypo- and hypersegmented forms), suggestive of pseudo-Pelger-Huët anomaly. Methylprednisolone treatment resulted in progressive improvement of pyoderma gangrenosum.

Keywords: pseudo-Pelger-Huët, pyoderma gangrenosum

Introduction

Pyoderma gangrenosum (PG) is a neutrophilic dermatosis associated with systemic diseases in about 50% of cases, including myelodysplastic syndrome and acute myeloid leukemia [1]. Myelodysplastic syndrome and acute myeloid leukemia can be associated with the pseudo-Pelger-Huët anomaly, a condition in which almost all the granulocytes (mostly neutrophils) are hyposegmented and/or hypogranulated [2-3]. About 75% of patients with myelodysplastic syndrome have peripheral neutrophils exhibiting

pseudo-Pelger-Huët anomaly, yet the condition has also been very rarely reported in neutrophils infiltrating the skin in pyoderma gangrenosum and in neutrophilic dermatoses associated with myelodysplastic syndrome or acute myeloid leukemia; it has also been reported following the administration of drugs that alter granulopoiesis [4-6]. We report the case of a patient with PG associated with idiopathic myelofibrosis showing pseudo-Pelger-Huët anomaly within neutrophils infiltrating the skin.

Case Synopsis

A 70-year-old man presented for a right lower limb wound following accidental trauma two weeks before. Owing to the progressive extension of the wound and the appearance of swelling and fever with shivering, his family doctor had prescribed amoxicillin/clavulanate 1g every 8 hours, which was ineffective. His medical history was significant for idiopathic myelofibrosis (*CALR* mutated, (type 1) and negative for V617F mutation of *JAK2*) treated with ruxolitinib. He was also being treated with metoprolol, perindopril, and allopurinol. On physical examination, there was edema of the ankle, forefoot, and lower third of the leg; on the latter, there was a 2x1cm, lightly exuding ulcer with adjacent serum-containing blisters. The surrounding skin was erythematous, slightly edematous, and tender on palpation. The patient was shivering with a body temperature of 38.9C; the heart rate was 95 bpm, blood pressure 130/80mmHg, and oxygen saturation 96% on room air. Blood examinations

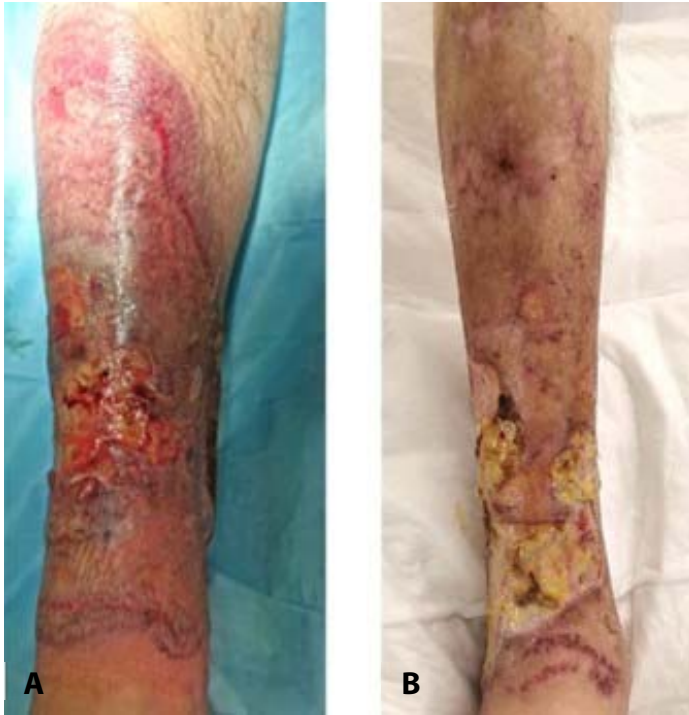

Figure 1. A): Expanding ulcer with violaceous undermined border during hospitalization. **B)** Cutaneous presentation following two weeks of corticosteroidal treatment.

revealed an elevated C-reactive protein 92mg/dL, procalcitonin 0.14ng/mL, white blood cells 8,440/mm³ (with 4,800 neutrophils/mm³), hemoglobin 9.7g/dL, and prothrombin time-international normalized ratio 1.32. Electrolytes and liver and renal function tests were normal. A nasopharyngeal swab for SARS-CoV-2 RNA was negative. An X-ray of the right leg showed no fractures and a Doppler ultrasound of the lower limbs was negative for deep vein thrombosis or abscesses.

The patient was admitted to the internal medicine ward where a wound culture was performed that identified the presence of *Pseudomonas aeruginosa* and *Staphylococcus aureus*. Intravenous antibiotic therapy with piperacillin/tazobactam and vancomycin was prescribed for 10 days. Despite the antibiotic treatment, however, there was a progressive increase in the size of the ulcer such that it extended to the entire right tibial area and exhibited a fibrinous base and undermined edges (**Figure 1A**). A dermatological consultation suggested a diagnosis of pyoderma gangrenosum and treatment was initiated with intravenous methylprednisolone 60mg daily and wound care

with collagenase, topical rifamycin, and hydrocolloid medications. Furthermore, ruxolitinib was replaced with hydroxyurea. In the following few days, body temperature returned to normal and there was a reduction in the cutaneous perilesional inflammation.

Histological examination (**Figure 2**) showed a marked nodular and diffuse pandermal infiltrate with initial extension to the subcutaneous tissue, consisting of neutrophils with features of dysmaturity and segmentation anomalies (hypo- and hypersegmented forms). The infiltrate also involved the epidermis, where some spongiosis and reticular degeneration of the keratinocytes was observed. Furthermore, there was collagen lysis within the neutrophilic infiltrate. Immunohistochemistry documented the majority of the cell infiltrate was positive for CD15, myeloperoxidase and MMDA and negative for CD68, CD163, CD10, CD13, CD123, CD34 and CD4 (**Figure 3**), thus confirming its granulocytic nature. No elements attributable to leukemic blasts were found. Histologic stainings for infectious agents were all negative.

Two weeks after corticosteroidal treatment initiation, there was a partial reduction of the

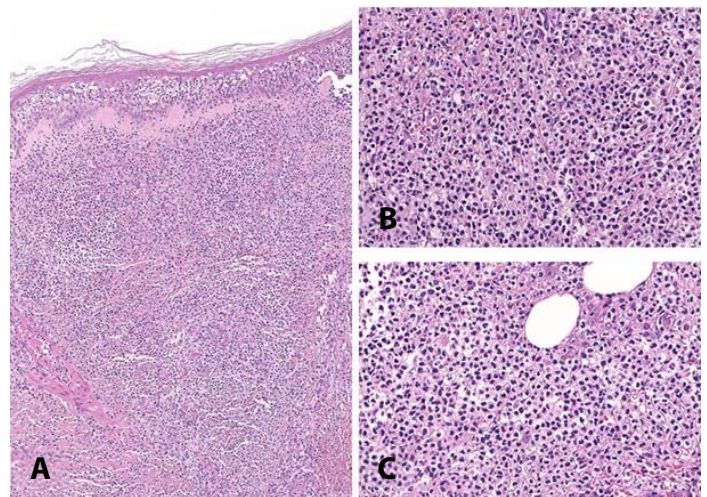


Figure 2. A) Histological examination of a 5mm skin punch biopsy taken from the ulcer. Superior border shows a marked dermal infiltrate consisting of neutrophils with epidermal spongiosis and exocytosis of neutrophils with associated collagen necrosis. H&E, 10×. **B, C)** Neutrophils within the infiltrate show features of dysmaturity and segmentation anomalies (hypo- and hypersegmented forms). H&E, 40×.

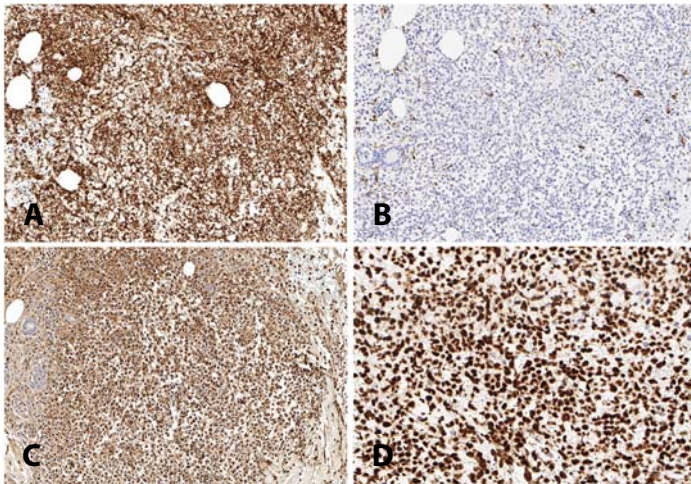


Figure 3. Immunohistochemical staining of biopsy with **A)** CD15, 20x; **B)** CD68, 1.3x; **C)** myeloperoxidase, 20x; **D)** myeloid cell nuclear differentiation antigen (MNSA), 40x.

perilesional erythema and stabilization of the ulcer size (**Figure 1B**). Corticosteroid therapy was gradually tapered to oral prednisone 25mg daily and the patient was discharged. At a 1-month follow-up, further improvement was noted and prednisone treatment was tapered to a maintenance dose of 5mg daily.

Case Discussion

Pyoderma gangrenosum is a non-infectious neutrophilic dermatosis that usually affects the lower limbs. It most commonly presents with sterile pustules that evolve into painful ulcerations with erythematous-purplish undermined edges. The most common associations include rheumatoid arthritis, inflammatory bowel diseases, and hematological diseases, especially myelodysplastic

syndrome and acute myeloid leukemia [1]. Atypical or bullous pyoderma gangrenosum is frequently associated with hematological neoplasms [1].

Regarding neutrophil segmentation anomalies, Pelger-Huët anomaly is a rare, hereditary, condition characterized by a lack of nuclear maturation with consequent hyposegmentation of neutrophils, eosinophils, and basophils; monocytes may also appear with a rounded core, without indentations (**Table 1**), [7]. It is inherited in an autosomal-dominant pattern and is caused by mutations in the laminin B receptor, a protein that binds B-type laminins and heterochromatin, and plays a crucial role in the nuclear segmentation of polymorphonuclear leukocytes [7]. Of note, cells with Pelger-Huët anomaly have a normal life span and possess normal phagocytizing and killing functions. Pseudo-Pelger-Huët anomaly refers to a morphologically similar condition in which granulocytes are hyposegmented but occurs secondary to acquired pathologies, such as myelodysplastic syndrome, acute myeloid leukemia, myeloproliferative disorders, and infections (e.g., HIV, *Leishmania*) but may also occur following the administration of drugs that alter the granulopoiesis (**Table 1**) like tacrolimus and mycophenolate mofetil in allogeneic transplant recipients [4-6]. It is reportedly caused by acquired clonal mutations or reduced expression of the laminin B receptor [7]. Ultimately, hypersegmented neutrophils represent another neutrophil segmentation anomaly characterized by the presence of more than 3% of neutrophils with at least five lobes (**Table 1**). Such an anomaly is observed in a number of disorders, such

Table 1. Characteristics of neutrophil segmentation anomalies.

	Pelger-Huët anomaly	Pseudo-Pelger-Huët anomaly	Neutrophil hypersegmentation
Pathology features	Hyposegmented neutrophil nuclei	Hyposegmented neutrophil nuclei	Neutrophil nuclei with more than 5 lobes
Etiology	Autosomal dominant LBR (laminin β receptor) mutation	Myelodysplastic syndrome, acute myeloid leukemia, myeloproliferative disorders, infections (e.g., HIV, <i>Leishmania</i>), drugs	Nutrient deficiency (vitamin B12, folic acid, iron), drugs, myelodysplastic syndrome, myeloproliferative disorders
Neutrophilic dermatoses exhibiting neutrophil segmentation anomalies	-	Pyoderma gangrenosum, Sweet syndrome, neutrophilic panniculitis, Behçet disease	-

as megaloblastic anemia (due to folic acid or vitamin B12 deficiency, including pernicious anemia), iron deficiency, myelodysplastic syndrome, myeloproliferative disorders, chronic infections, and in association with drugs such as chemotherapy.

As to the pseudo-Pelger-Huët anomaly, very few cases occurring in cutaneous biopsies have been reported. Morioka et al. reported two patients with myelodysplastic syndrome who developed neutrophilic dermatosis and in whose cutaneous biopsies marked infiltration by neutrophils with nuclear anomalies, i.e., hyposegmentation (pseudo-Pelger-Huët anomaly) or hypersegmentation [5]. Notably, similar anomalies were also observed in the peripheral blood and bone marrow neutrophils. The authors also reviewed cutaneous biopsy specimens from six patients with neutrophilic dermatoses associated with myelodysplastic syndrome and reported that 7.5% to 13.5% of the neutrophils in the skin infiltrates of these patients displayed pseudo-Pelger-Huët anomaly [5]. Kim et al. reported another case of myelodysplastic syndrome-associated neutrophilic dermatosis in which infiltrated neutrophils exhibited pseudo-Pelger-Huët anomaly. In that case, there was a rapid and aggressive clinical course, which led the authors to hypothesize that

pseudo-Pelger-Huët anomaly could be a poor prognostic marker [8]. Chiang et al. described a case of pyoderma gangrenosum in an 80-year-old patient with myelodysplastic syndrome in which the great majority of neutrophils within the dermal infiltrate exhibited pseudo-Pelger-Huët anomaly [4]. Furthermore, nuclear segmentation anomalies have been described in cutaneous biopsies of Sweet syndrome and neutrophilic panniculitis associated with myelodysplastic syndrome [9,10].

Conclusion

The present case describes the occurrence of the pseudo-Pelger-Huët anomaly in pyoderma gangrenosum in a patient with idiopathic myelofibrosis. Hence, the recognition of this anomaly on histology also carries clinical implications, as it should prompt physicians to exclude associated underlying hematologic disorders such as myelodysplastic syndrome or myeloproliferative neoplasms.

Potential conflicts of interest

The authors declare no conflicts of interest.

References

1. Maverakis E, Marzano AV, Le ST, et al. Pyoderma gangrenosum. *Nat Rev Dis Primers*. 2020;6:81. [PMID: 33033263].
2. Dusse LM, Moreira AM, Vieira LM, et al. Acquired Pelger-Huët: what does it really mean? *Clin Chim Acta*. 2010;411:1587-90. [PMID: 20691170].
3. Wang E, Boswell E, Siddiqi I, et al. Pseudo-Pelger-Huët anomaly induced by medications: a clinicopathologic study in comparison with myelodysplastic syndrome-related pseudo-Pelger-Huët anomaly. *Am J Clin Pathol*. 2011;135:291-303. [PMID: 21228370].
4. Chiang M, Fleming M. The pseudo-Pelger-Huët anomaly in pyoderma gangrenosum associated with myelodysplastic syndrome. *Am J Dermatopathol*. 2007;29:293-5. [PMID: 17519630].
5. Morioka N, Otsuka F, Nogita T, et al. Neutrophilic dermatosis with myelodysplastic syndrome: nuclear segmentation anomalies of neutrophils in the skin lesion and in peripheral blood. *J Am Acad Dermatol*. 1990;23:247-249. [PMID: 2212120].
6. Nogita T, Morioka N, Ishibashi Y, et al. Pelgeroid-like anomalous cells in the diagnosis of neutrophilic dermatosis associated with myelodysplastic syndrome. *Int J Dermatol*. 1992;31:864-865. [PMID: 1478765].
7. Colella R, Hollensead SC. Understanding and recognizing the Pelger-Huët anomaly. *Am J Clin Pathol*. 2012;137:358-66. [PMID: 22338047].
8. Kim SJ, Seo JJ, Lee SC, et al. Unusual cutaneous neutrophilic infiltration in myelodysplasia syndrome: a nuclear segmentation anomaly. *Ann Dermatol*. 1998;10:270-273. [DOI: 10.5021/ad.1998.10.4.270].
9. Shin MK, Oh YJ, Yoon HJ, et al. Subcutaneous Sweet syndrome with nuclear segmentation anomalies: a diagnostic marker of myelodysplasia. *Int J Dermatol*. 2012;51:976-8. [PMID: 22788818].
10. Becherer K, Golda N, Feldman M, et al. Neutrophilic panniculitis associated with myelodysplastic syndrome with abnormal nuclear forms. *J Cutan Pathol*. 2009;36:1024-6. [PMID: 19674208].