

UC Davis

Dermatology Online Journal

Title

Cutaneous T-cell lymphoma developing during nivolumab treatment for metastatic melanoma

Permalink

<https://escholarship.org/uc/item/05z8g6c7>

Journal

Dermatology Online Journal, 28(1)

Authors

Hida, Yasutoshi
Kageji, Riho
Bekku, Hirofumi
[et al.](#)

Publication Date

2022

DOI

10.5070/D328157071

Copyright Information

Copyright 2022 by the author(s). This work is made available under the terms of a Creative Commons Attribution-NonCommercial-NoDerivatives License, available at <https://creativecommons.org/licenses/by-nc-nd/4.0/>

Peer reviewed

Cutaneous T-cell lymphoma developing during nivolumab treatment for metastatic melanoma

Yasutoshi Hida¹ MD PhD, Riho Kageji¹ MD, Hirofumi Bekku² MD, Shunsuke Watanabe³ MD, Takuya Seike⁴ MD PhD, Michiko Yamashita⁵ MD PhD

Affiliations: ¹Division of Dermatology, Tokushima Red Cross Hospital, Komatsushima, Tokushima, Japan, ²Division of Hematology, Tokushima Red Cross Hospital, Komatsushima, Tokushima, Japan, ³Division of Diagnostic Pathology, Tokushima Red Cross Hospital, Komatsushima, Tokushima, Japan, ⁴Division of Plastic and Reconstructive Surgery, Tokushima Red Cross Hospital, Komatsushima, Tokushima, Japan, ⁵Department of Health Science, Tokushima University, Tokushima, Tokushima, Japan

Corresponding Author: Yasutoshi Hida, Division of Dermatology, Tokushima Red Cross Hospital, 773-8502, Tokushima Komatsushima, Komatsushima-cho, Irinoguchi 103, Japan, Tel: 81-885-32-2555/Fax: 81-885-32-0719, Email: yasutoshi@ae.auone-net.jp

Keywords: cutaneous, inhibitor, lymphoma, malignant melanoma, nivolumab, PD1, programmed cell death-1, T cell

To the Editor:

Programmed cell death-1 (PD1) inhibitors improve outcomes in many malignancies. However, PD1 has been reported to be a tumor suppressor in T cells [1, 2]. Four cases of T-cell lymphoma related to PD1 inhibitors have been reported [2-5]. Herein, we report a case of cutaneous T-cell lymphoma developing during PD1 inhibitor therapy.

A 56-year-old man presented with a black tumor on his right heel. After an excisional biopsy, the tumor was diagnosed as malignant melanoma (MM),

(Breslow thickness 10 mm, BRAF V600 mutation negative). A sentinel lymph node biopsy was negative and positron emission tomography (PET)-computed tomography (CT) images revealed no evidence of distant metastasis. An additional resection was then performed. Six months after the operation, PET-CT images revealed metastasis in pelvic lymph nodes and adrenal glands. The administration of nivolumab was started. The metastases shrank immediately. After 1.5 years of nivolumab, two subcutaneous tumors appeared on the left thigh. Excisional biopsy revealed massive infiltration of atypical lymphoid cells (**Figure 1**). Immunohistochemically, the lymphoid cells were positive for CD3, CD8, T cell intracellular antigen-1,

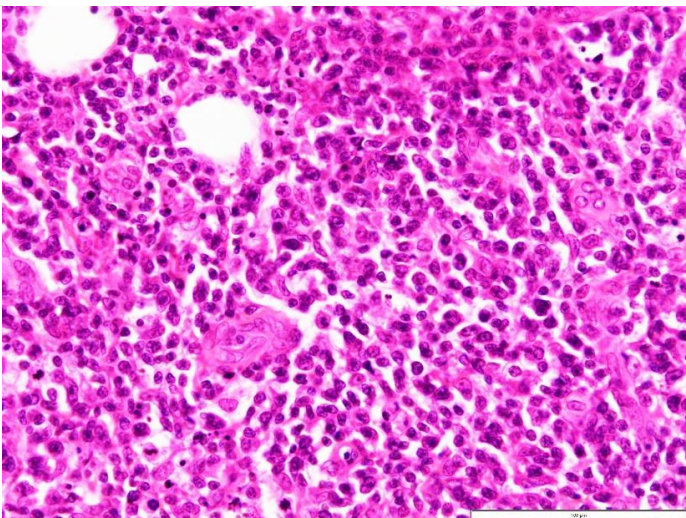


Figure 1. H&E histopathological findings showed atypical lymphoid cells with irregular nuclei infiltrated. Bar, 100µm.

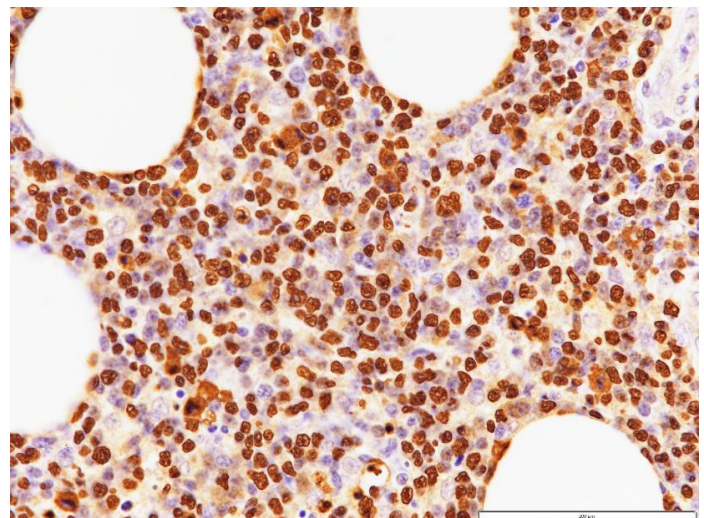


Figure 2. In situ hybridization with an Epstein-Barr virus encoding region probe showed positivity. Bar, 200µm.

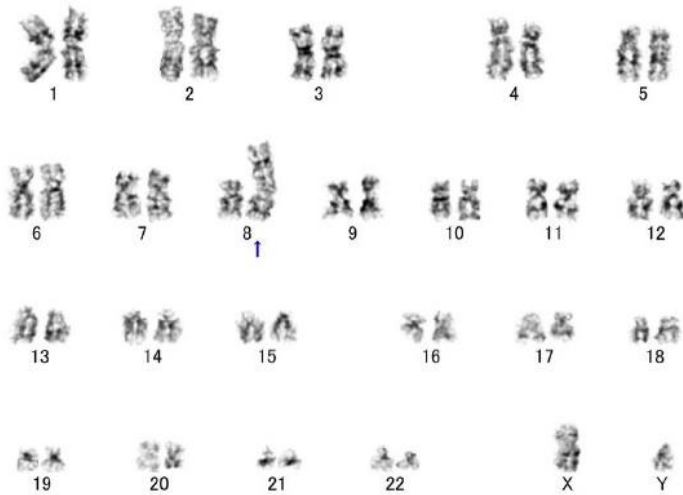


Figure 3. Chromosome examination using the G-band showed 46XY, der (8) t (1; 8), (q12;p23). Arrow indicates site of translocations.

and granzyme B; CD4 and CD56 were negative. The latent form of the Epstein-Barr virus (EBV) was detected by in situ hybridization with a probe from Epstein-Barr virus encoding region (**Figure 2**). Chromosome examination using the G-band of this tumor revealed chromosomal abnormalities (46XY, der (8) t (1; 8), (q12; p23)) in 18 of 20 cells (**Figure 3**). A diagnosis of cutaneous T-cell lymphoma was made based on these findings. He underwent three cycles of CHOP chemotherapy (cyclophosphamide, doxorubicin, vincristine, and prednisolone). One

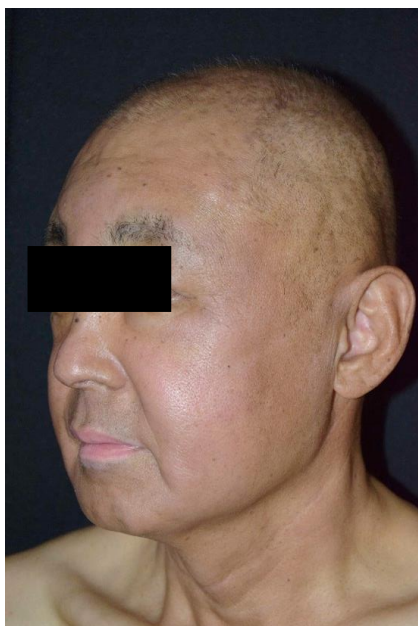

Figure 4. Clinical features showed multiple erythematous indurated plaques on the face.

month after the chemotherapy, multiple tender erythematous and indurated plaques appeared on the face, trunk, and proximal limbs (**Figure 4**). PET-CT showed numerous hypermetabolic subcutaneous nodules throughout the body (**Figure 5**). Skin biopsy specimens showed atypical lymphoid cell infiltration in the subcutaneous tissue in a lobular panniculitis-like pattern. We considered CHOP therapy ineffective and started DeVIC chemotherapy (dexamethasone, etoposide, ifosfamide, and carboplatin). After two courses of DeVIC, multiple plaques completely disappeared and numerous hypermetabolic nodules on PET-CT also disappeared, except for pelvic melanoma metastases. The patient is currently receiving an injection of interferon β every four weeks.

Wartewig et al. discovered that PD1 was a tumor suppressor in T-cell lymphoma using an in vivo model mouse [1]. Anard et al. reported a patient who developed T-cell lymphoma after treatment with pembrolizumab, a PD1 inhibitor [2]. Before using a PD1 inhibitor, a T cell clone that carries the ten-eleven translocation two (TET2) mutation presented in biopsy samples at low frequency. After using a PD1 inhibitor, T cell clones carrying the TET2 mutation undergo massive expansion of the most dominant clone, leading to lymphoma. They postulated that

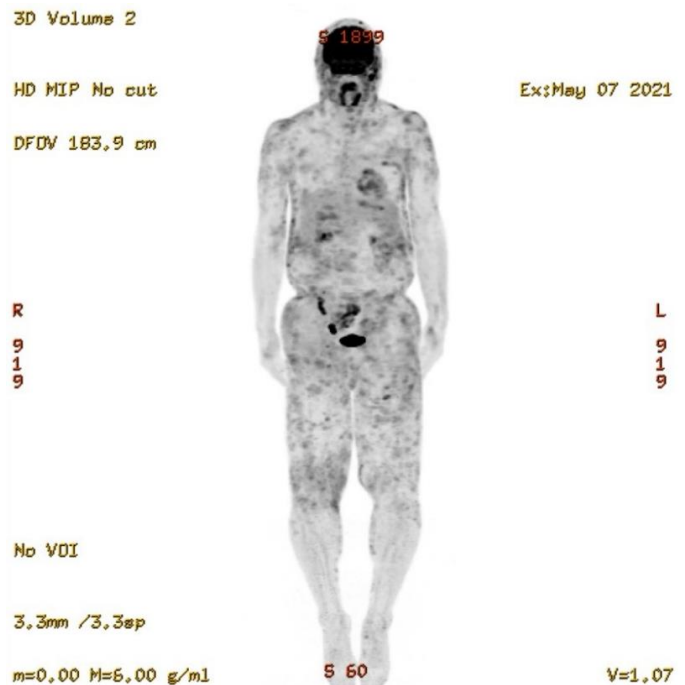


Figure 5. PET-CT showed numerous hypermetabolic subcutaneous nodules in the whole body.

PD1 inhibitors cause monoclonal expansion of mutated T cell clones causing T-cell lymphoma. We assumed in the current case that EBV-infected genetically abnormal T cell clones proliferated in monoclonal expansion, leading to lymphoma. In conclusion, PD1 inhibitors should be used with caution in patients who might have T cell clones with

genetic abnormalities, such as those with a history of EBV infection.

Potential conflicts of interest

The authors declare no conflicts of interest.

References

1. 1 Wartewig T, Kurgys Z, Keppler S, et al. PD1 is a haploinsufficient suppressor of T cell lymphomagenesis. *Nature*. 2017;552:121-125. [PMID: 29143824].
2. 2 Anand K, Ensor J, Pingali SR, et al. T-cell lymphoma secondary to checkpoint inhibitor therapy. *J Immunother Cancer*. 2020;8:e000104. [PMID: 32114498].
3. 3 Marks JA, Parker DC, Garrot LC, Lechowicz MJ. Nivolumab-associated cutaneous T-cell lymphoma. *JAAD Case Reports*. 2021;9:39-41. [PMID: 33644277].
4. 4 Zheng YJ, Lee A, Pincus L, et al. Cutaneous CD56⁺ T-cell lymphoma developing during pembrolizumab treatment for metastatic melanoma. *JAAD Case Reports*. 2018;4:540-542. [PMID: 29892669].
5. 5 Koda K, Toyoshima M, Yazawa S, et al. CD8-positive peripheral T cell lymphoma in a patient following long-term nivolumab for advanced lung adenocarcinoma: A case report. *Thorac Cancer*. 2021;12: 1765-1769. [PMID: 33939308].