

# UC Davis

## Dermatology Online Journal

### Title

Mycobacterium fortuitum infection after acupuncture treatment

### Permalink

<https://escholarship.org/uc/item/0572r5gp>

### Journal

Dermatology Online Journal, 23(9)

### Authors

Gracia-Cazaña, T  
Milagro, A  
Queipo, F  
et al.

### Publication Date

2017

### DOI

10.5070/D3239036500

### Copyright Information

Copyright 2017 by the author(s). This work is made available under the terms of a Creative Commons Attribution-NonCommercial-NoDerivatives License, available at <https://creativecommons.org/licenses/by-nc-nd/4.0/>

# *Mycobacterium fortuitum* infection after acupuncture treatment

T Gracia-Cazaña<sup>1</sup> MD, A Milagro<sup>2</sup> MD, F Queipo<sup>3</sup> MD PhD, Y Gilaberte<sup>4</sup> MP MD PhD

Affiliations: <sup>1</sup>Department of Dermatology, Hospital de Barbastro, Huesca, Spain <sup>2</sup>Department of Microbiology, Hospital San Jorge, Huesca, Spain <sup>3</sup>Department of Pathology, Hospital San Jorge, Huesca, Spain <sup>4</sup>Department of Dermatology, Hospital San Jorge, Huesca, Spain

Corresponding Author: Dr. T. Gracia-Cazaña, Department of Dermatology, Hospital de Barbastro, Huesca. Av Pirineos nº 11 1ªA, PO Box: 22011 – Barbastro, Huesca (Spain), Tel: 34-657571403, E-mail: tamgracaz@gmail.com

## Abstract

Acupuncture is an invasive intervention and it is essential to maintain asepsis of the skin; infections may result when not carried out properly. We present a patient who developed an infection with *Mycobacterium fortuitum* after acupuncture. Few cases of non-tuberculous mycobacteria (NTM) have been published; the least frequently reported in the literature is *Mycobacterium fortuitum*. Clinicians should suspect NTM infection when evaluating a persistent and resistant deep cutaneous infection, especially if the patient is immunocompromised or has a history of skin injury.

**Keywords:** atypical *Mycobacterium*, nontuberculous mycobacteria, acupuncture

## Introduction

Acupuncture has been practiced since ancient times in the East and its use is increasing considerably in Occidental countries as a complementary health therapy. It is an invasive intervention, in which needles of 2 to 3 cm are inserted. For this reason, caution is necessary in relation to the asepsis of the skin [1]. Poor technique can lead to infections [2].

## Case Synopsis

A 51-year-old immunocompetent woman was referred from the emergency department for skin abscesses located on the abdomen with 1 month of evolution. The condition had been treated with oral amoxicillin (750mg 3/day) for 3 weeks without improvement. The patient reported that the lesions

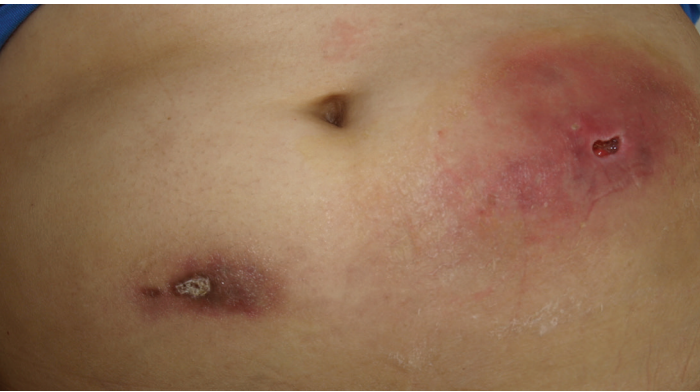
began as nodules that ulcerated. Three months earlier the patient had undergone six sessions of acupuncture in that area.

Physical examination revealed edematous and erythematous plaques of 6x4 cm and 3x2 cm on both flanks and periumbilical area, in addition to subcutaneous nodules at the punctures sites (**Figure 1**).

A biopsy and culture for microbiological analysis (bacteria, mycobacteria and fungi) was performed and subsequently treatment with cloxacillin 500 mg every 6 hours was initiated. Histopathology revealed caseation necrosis surrounded by multinucleated giant cells, lymphocytes, and epithelioid histiocytes. The culture for bacteria and fungi were negative. However, an acid-fast bacillus was isolated on Lowenstein-Jensen media after five days of incubation at 37°C; this was identified as *Mycobacterium fortuitum* by polymerase chain reaction hybridization using the rpoB gene. The isolated bacillus was susceptible to doxycycline, amikacin, clarithromycin, minocycline, ciprofloxacin, and imipenem. The patient was treated with ciprofloxacin (500 mg twice daily) and doxycycline (100 mg twice daily) for seven months with clinical and microbiological resolution. Follow up for one year after cessation of treatment has revealed no recurrence.

## Case Discussion

NTM (non-tuberculous mycobacteria) are immobile and non-encapsulated anaerobic bacilli that do not form spores, and contain a high lipid composition. Fifty species that cause infections have been



**Figure 1.** Ulcerated erythematous plaques on the abdomen skin.

identified and the NTM infection incidence has increased worldwide owing to immunosuppression and HIV/AIDS states. *M. fortuitum* was first described from a human postinjection abscess and published by da Costa-Cruz [3]. Since then, the infections related to this mycobacterium are generally associated with the use of contaminated solutions and/or equipment during medical procedures [4, 5]. There are reports of NTM, in particular *M. fortuitum*, infection caused by tattooing [6], mesotherapy [7], acupoint embedding therapy (AET), [4], and acupuncture [1].

Until now, among the reported cases of NTM associated with acupuncture, the most frequently isolated has been *M. abscessus* [1]. Currently, there are three published cases of *M. fortuitum* infection after acupuncture, all in immunocompetent women with an age range from 23 to 65 years old. These infections have been located on the sole, the limbs, and the thighs [8-10]. The first case was published by Cordeiro et al., a 41-year-old woman who was infected when she used unclean needles [8]. Lee et al. described 9 *M. fortuitum* infections in their series of 29 NTM. In one of them the inoculation mechanism was related to acupuncture on the sole [9]. Finally, Guevara et al. reported a 23-year-old woman with limb injuries after acupuncture with infected needles, linking quaternary ammonium, which is widely used as a disinfectant in Venezuela, as a possible source of infection [10].

## Conclusion

Clinicians should suspect NTM infection when evaluating a persistent and resistant deep cutaneous infection, especially if the patient is immunocompromised or has a history of skin injury. We also highlight the need for safety measures

in acupuncture clinics with strict regulation of disinfection to prevent occurrence of harmful infections.

## References

1. Gnatta JR, Kurebayashi LF, Paes da Silva MJ. Atypical mycobacterias associated to acupuncture: an integrative review. *Rev Lat Am Enfermagem*. 2013 Feb;21(1):450-8. [PMID: 23546331].
2. White A. A cumulative review of the range and incidence of significant adverse events associated with acupuncture. *Acupunct Med*. 2004 Sep;22(3):122-33. [PMID: 15551936].
3. da Costa Cruz JC. [Mycobacterium fortuitum: new acid fast bacillus pathogenic for man]. *Acta Med (Rio de Janeiro)*. 1938;1:298-301.
4. Noh TK, Won CH, Lee MW, Choi JH, Lee SO, Chang SE. Infection with Mycobacterium fortuitum during acupoint embedding therapy. *J Am Acad Dermatol*. 2014 Jun;70(6):e134-5. [PMID: 24831334].
5. Fowler J, Mahlen SD. Localized cutaneous infections in immunocompetent individuals due to rapidly growing mycobacteria. *Arch Pathol Lab Med*. 2014 Aug;138(8):1106-9. [PMID: 25076301].
6. Philips RC, Hunter-Ellul LA, Martin JE, Wilkerson MG. Mycobacterium fortuitum infection arising in a new tattoo. *Dermatol Online J*. 2014 Jun 15;20(6). [PMID: 24945647].
7. Quiñones C, Ramalle-Gómara E, Perucha M, Lezaun ME, Fernández-Vilariño E, García-Morrás P, Simal G. An outbreak of Mycobacterium fortuitum cutaneous infection associated with mesotherapy. *J Eur Acad Dermatol Venereol*. 2010 May;24(5):604-6. [PMID: 19840199].
8. Cordeiro MR, Mascarenhas R, Reis JP, Tellechea O, Figueiredo A. Mycobacterial infection after acupuncture. *JEADV*. 2003 Nov;17 Suppl 3:186.
9. Lee WJ, Kang SM, Sung H, Won CH, Chang SE, Lee MW, et al. Non-tuberculous mycobacterial infections of the skin: a retrospective study of 29 cases. *J Dermatol*. 2010 Nov;37(11):965-72. [PMID: 21039785].
10. Guevara-Patiño A, Sandoval de Mora M, Farreras A, Rivera-Olivero I, Fermin D, de Waard JH. Soft tissue infection due to Mycobacterium fortuitum following acupuncture: a case report and review of the literature. *J Infect Dev Ctries*. 2010 Sep 3;4(8):521-5. [PMID: 20818105].