

Photo Vignette

A metastatic cancer to skin in an otherwise asymptomatic young man: an unusual presentation

Rahmatollah Salmanpoor¹, Nasrin Saki², Mojdeh Sepaskhah¹, Fatemeh Sari Aslani³, Bahareh Kardeh⁴

Dermatology Online Journal 19 (10): 14

¹**Cutaneous Leishmaniasis Research Center, Dermatology Department, Shiraz University of Medical Sciences, Shiraz, Iran.**

²**Cutaneous Leishmaniasis Research Center and student research committee' Dermatology Department, Shiraz University of Medical Sciences, Shiraz, Iran.**

³**Cutaneous Leishmaniasis Research Center, Pathology Department, Shiraz University of Medical Sciences, Shiraz, Iran.**

⁴**Student research committee, Shiraz University of Medical Sciences, Shiraz, Iran.**

Correspondence:

Nasrin Saki
Department of Dermatology, Shahid Faghihi Hospital
Zand Avenue
Shiraz, Iran
Tel/fax: 0098-711-2319049

Abstract

Cutaneous metastasis is a rare complication of visceral malignancies. We present a very unusual case of a 33 year-old seemingly healthy man with a sudden and rapidly enlarging skin lesion that was diagnosed as a skin metastasis of his visceral malignancy. Abdominopelvic CT scan revealed thickening of the anterior wall of the urinary bladder and the fundus and body of the stomach. Skin biopsy histopathological findings were suggestive of poorly differentiated metastatic carcinoma. The origin of the primary carcinoma was bladder adenocarcinoma or/and gastric adenocarcinoma, but the tumor was so poorly differentiated that the original source of the tumor could not be defined with certainty.

Key Words: Cutaneous Metastasis, Visceral malignancy, poorly-differentiated carcinoma.

Introduction

Cutaneous metastases of internal malignancies have been estimated to present in 0.6% to 10.4% of patients and account for 2% of all skin malignancies [1]. The relative frequency of metastatic skin diseases conforms to that of primary malignancies i.e. breast cancer, colon cancer, and melanoma are in the top of the list in females and lung cancer, colon cancer, and melanoma are the most common in males [2]. Metastases of the urinary bladder or of gastric origin are quite infrequent. Rarely skin metastasis could be the first sign of a hidden internal malignancy [1]. Herein we describe a very unusual case of a young man with an unusual presenting skin lesion that was confirmed to be a skin metastasis of his undiagnosed visceral carcinoma.

Case History

We present a 33 year-old man with a sudden onset of an extensive, rapidly growing, indurated, firm violaceous tumor on his back for 2 months; he was referred to Faghihi dermatology clinic, Shiraz, Iran. The patient was relatively well before that time. He had no history of previous infection or trauma and was otherwise healthy. There was no family history of any significant diseases.

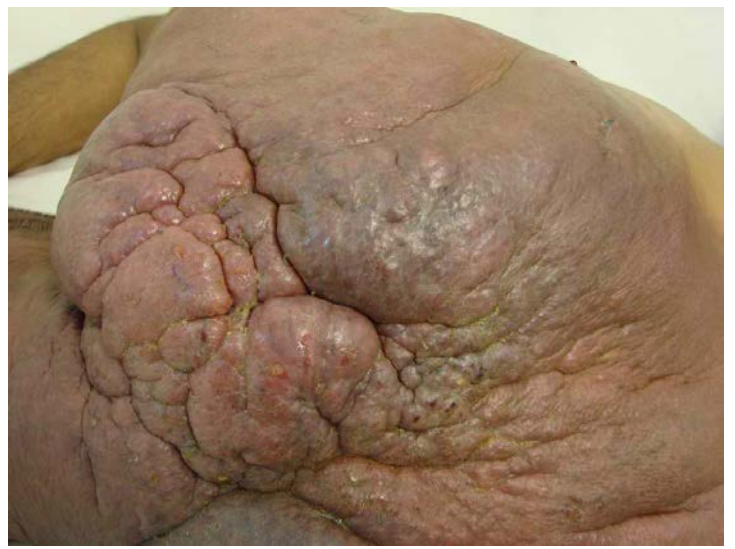
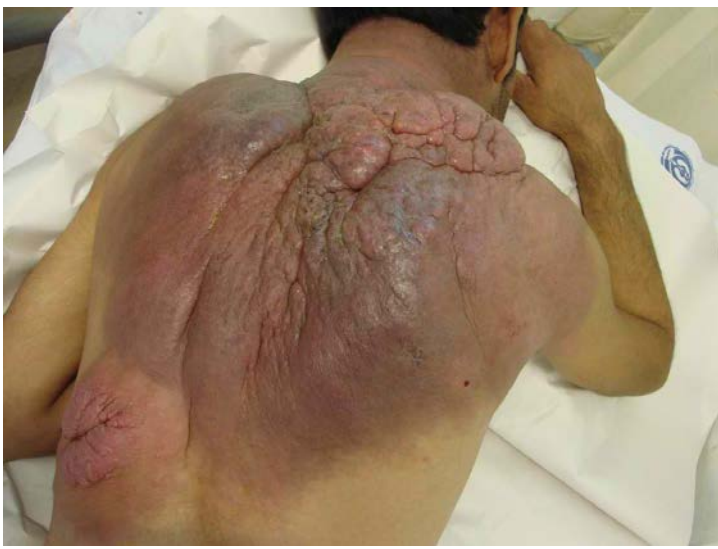
Figure 1. An erythematous violaceous indurated plaque with ill-defined borders and woody induration on the whole back and posterior neck

Figure 2. Significant thickening of the skin and subcutaneous tissues

On dermatological examination, there was an erythematous violaceous firm plaque with ill-defined borders and woody induration on his whole back and posterior neck. General physical examination was normal. FBS (fasting blood glucose) and serum immunoelectrophoresis tests were done and the results were all normal. CBC (complete blood count), ESR (erythrocyte sedimentation rate), LFT (liver function test), stool guaiac test and urinalysis were also normal. An excisional biopsy of skin was done. Histologic examination showed an ill-defined dermal tumor infiltrating the subcutaneous fat and separated from the epidermis by a grenz zone. The tumor cells dissecting the collagen fibers had oval to spindle shaped nuclei, some with conspicuous nucleoli, and ill-defined cell borders. Some mitotic figures were seen. There was no gland formation. Immunohistochemical study on formalin fixed paraffin embedded tissue was performed. The tumor cells were positive for cytokeratin (AE1/AE3), CK7, CK20, EMA, and vimentin, but were negative for LCA, p63, NSE, CD34, SMA, S100, and calretinin. The immunohistochemical profile was favored poorly differentiated carcinoma. Because CK7+/CK20+ tumors indicate urothelial carcinoma, pancreatic ductal adenocarcinoma, bladder adenocarcinoma, gastric adenocarcinoma, and cholangiocarcinoma, the primary source of the malignancy could be one of the mentioned types.

Spiral CT scan of the chest with contrast showed thickening of the soft tissues of the dorsal aspect of the chest, about 38 mm in thickest portion, with a possibility of tumoral infiltration. Spiral CT of the neck with contrast showed significant thickening of the skin and subcutaneous tissues, about 63 mm in the thickest portion. Abdominopelvic CT scan with contrast showed some isodense material in the perinephric space, enhancing thickening of the wall of the anterior aspect of the urinary bladder, free fluid in the peritoneal cavity, and thickening of the wall of the fundus and body of the stomach. The patient was referred to oncologists for the management of his metastatic cancer of gastric and/or bladder origin.

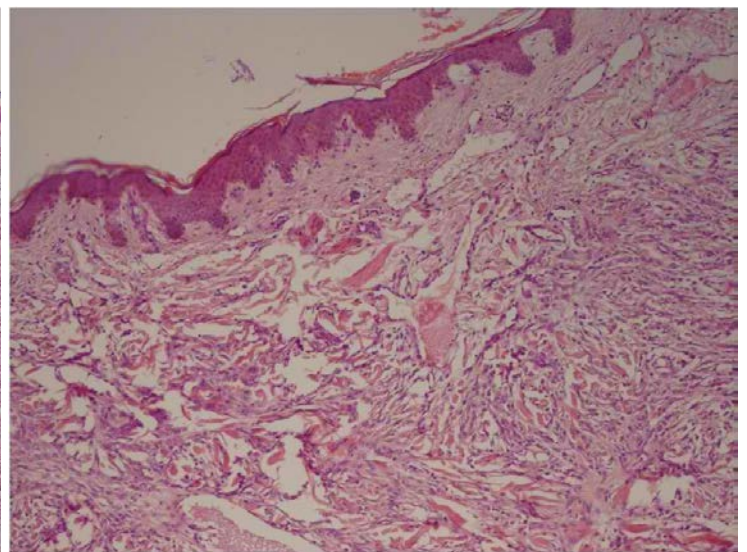
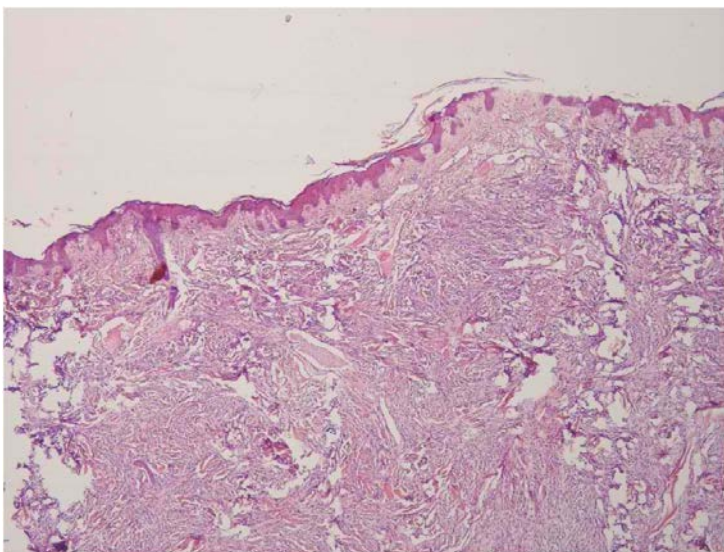


Figure 3. Extensive dermal involvement by tumor cells. (H&E X 40)

Figure 4. Tumor cells dissecting collagen bundles and separated from the epidermis by a grenz zone and dilated vessels. (H&E X200)

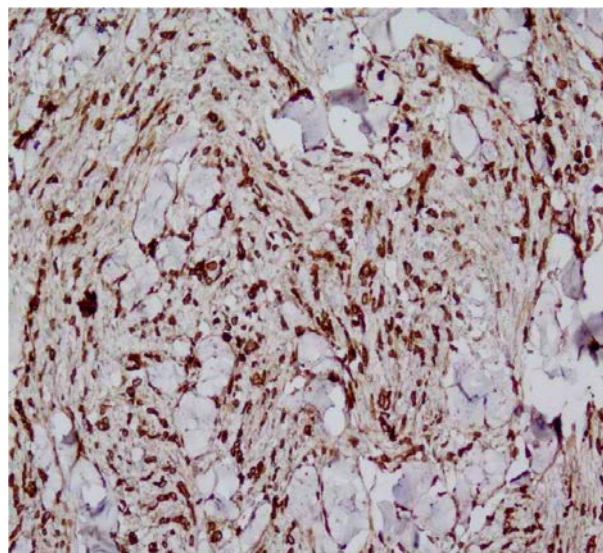
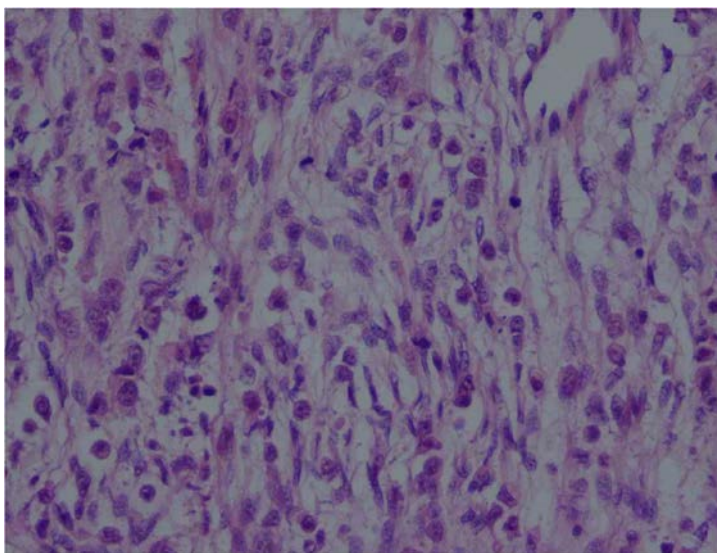


Figure 5. Tumor cells have predominantly oval to spindle shaped nuclei, some with conspicuous nucleoli. Some mitotic figures are present. (H&E X 400)

Figure 6. The tumor cells were diffuse and strongly positive for pan-cytokeratin. (IHC X 200)

Discussion

Cutaneous metastases may originate from an internal or a primary skin malignancy [3]. Skin metastases originating from visceral tumors are rarely the only manifestation of an undetected cancer, presenting at a late stage of the disease [4].

We report a very unusual case of a rapidly enlarging cutaneous tumor as the initial manifestation of an undiagnosed visceral malignancy in a previous seemingly healthy young man. Even complete blood work up, stool guaiac, urinalysis, and ESR did not show any abnormalities. Histopathologic investigations rendered clues to the origin of the skin carcinoma. As mentioned in the literature, CK7+/CK20+ tumors indicate urothelial carcinoma, pancreatic ductal adenocarcinoma, bladder adenocarcinoma, gastric adenocarcinoma, and cholangiocarcinoma. The tumor in our patient was so poorly differentiated that the original source of the tumor could not be defined with certainty.

Metastasis of bladder carcinoma to skin is quite uncommon [5]. This condition mostly affects middle-aged or elderly men and has a poor prognosis [6]. Skin metastases from upper digestive tract carcinomas have an incidence of about 1% [4].

Occurrence of cutaneous metastasis is usually an indicator of a poor outcome; an estimated survival of 2 to 34 weeks has been reported in the literature for these patients [4]. The most probable sites of skin metastases are different in each sex; the head and neck region and the anterior chest in men and the anterior chest wall and the abdomen in women are the areas which are mostly involved [3]. Cutaneous metastases have different tendencies for different regions. Breast and lung tumors usually involve the chest wall, whereas those of the gut, ovary, and bladder involve the abdomen. Invasion to scalp is rather uncommon and may have atypical presentations [7].

Skin metastasis may mimic specific dermatological conditions such as cysts, pyogenic granuloma, dermatofibroma, herpes zoster, alopecic patches, or erysipelas [3]. Cutaneous metastases might be solitary or multiple, and present as dermal papules, subcutaneous nodules, inflammatory patches, or fixed indurated lesions. The most common presentation is that of multiple nodules [7].

In a study evaluating the frequencies of different mechanisms of invasion to the skin, direct extensions had the highest rate, with local and distant metastases coming next. Distant metastasis was a rare mechanism [8].

References

1. Alcaraz I CL, Rütten A, Kutzner H, Requena L. Cutaneous metastases from internal malignancies: a clinicopathologic and immunohistochemical review. *Am J Dermatopathol.* 2012;34(4):347-93. [PMID: 22617133]
2. Schwartz RA. Cutaneous metastatic disease. *J Am Acad Dermatol* 1995;32(2 Pt 1):161-82. [PMID: 7622642]
3. Hussein MR. Skin metastasis: a pathologist's perspective. *J Cutan Pathol* 2010;37:e1-20. [PMID: 19922483]
4. Kairouani M PJ, Dietemann-Barabinot A, Diab R, Ruck S. Cutaneous metastasis revealing a relapse of gastric linitis: Another case. *Int J Surg Case Rep.* 2013;4(2):185-7. [PMID: 23276763]
5. Akman Y CK, Kavak A, Alper M. Extensive cutaneous metastasis of transitional cell carcinoma of the bladder. *Int J Urol* 2003;10(2):103-4. [PMID: 12588608]
6. Safer LF PD. Extensive cutaneous metastases from urinary bladder carcinoma. *Cutis* 1980;26(5):485-6. [PMID: 7460618]

7. Gül U KA, Gönül M, Külcü Cakmak S, Erinçkan C. Spectrum of cutaneous metastases in 1287 cases of internal malignancies: a study from Turkey. *Acta Derm Venereol.* 2007;87:160-2. [PMID: 17340025]
8. Lookingbill DP SN, Sexton FM. Skin involvement as the presenting sign of internal carcinoma. A retrospective study of 7316 cancer patients. *J Am Acad Dermatol* 1990;22:19-26. [PMID: 2298962]