

Paraneoplastic or treatment-associated dermatomyositis: a diagnostic challenge

Miguel Esperança-Martins^{1-3*} MD MSc, Sara Dâmaso^{1*} MD MSc, Nuno Carreira⁴ MD MSc, Bárbara Pena⁵ MD MSc, Catarina Correia⁵ MD MSc, Marta Aguado-Lobo⁶ MD MSc, Pablo Espinosa-Lara⁶ MD MSc, Luís Soares-de-Almeida^{6,7} MD PhD, Leonor Abreu Ribeiro¹ MD MSc, Luís Costa^{1,3} MD PhD

*Authors contributed equally

Affiliations: ¹Medical Oncology Department, Hospital de Santa Maria, Centro Hospitalar Universitário Lisboa Norte, Lisbon, Portugal, ²Vascular Biology & Cancer Microenvironment Laboratory, Instituto de Medicina Molecular João Lobo Antunes, Faculdade de Medicina, Universidade de Lisboa, Portugal, ³Translational Oncobiology Laboratory, Instituto de Medicina Molecular João Lobo Antunes, Faculdade de Medicina, Universidade de Lisboa, Portugal, ⁴Internal Medicine Department, Hospital de Santa Maria, Centro Hospitalar Universitário Lisboa Norte, Lisboa, Portugal, ⁵Clinical Pathology Department, Hospital de Santa Maria, Centro Hospitalar Universitário Lisboa Norte, Lisboa, Portugal, ⁶Dermatology Department, Hospital de Santa Maria, Centro Hospitalar Universitário Lisboa Norte, Lisboa, Portugal, ⁷Dermatology, Skin Biology and Pathology, Instituto de Medicina Molecular João Lobo Antunes, Faculdade de Medicina, Universidade de Lisboa, Portugal

Corresponding Authors: Miguel Esperança-Martins, Centro Hospitalar Universitário Lisboa Norte, Hospital de Santa Maria, Serviço de Oncologia Médica, Avenida Prof. Egas Moniz, sin numero, 1649-028 Lisboa, Portugal, Tel: 351-919393060, Email: miguelm martins@campus.ul.pt; Sara Dâmaso, Centro Hospitalar Universitário Lisboa Norte, Hospital de Santa Maria, Serviço de Oncologia Médica, Avenida Prof. Egas Moniz, sin numero, 1649-028 Lisboa, Portugal, Tel: 351-910584109, Email: sarafdamaso@gmail.com

Abstract

Dermatomyositis (DM) is a systemic autoimmune disorder characterized by proximal myopathy and dermatological findings. Approximately 15-30% of DM cases emerge as a paraneoplastic syndrome caused by a concomitant malignancy. Although more rare, in cancer patients DM has also been reported as a possible result of toxicity of some antineoplastic agents, such as taxanes and monoclonal antibodies. Herein, we report a 35-year-old woman with metastatic breast cancer who presented with skin lesions after initiation of paclitaxel and anti-HER2 agents. Clinical, laboratory, and histological findings were consistent with the diagnosis of DM.

Keywords: breast cancer, cutaneous toxicity, dermatomyositis, metastatic, paraneoplastic

Introduction

Dermatomyositis (DM), a systemic inflammatory autoimmune disorder, is characterized by proximal

myopathy and typical dermatological findings [1]. The incidence of DM is reported to be approximately 1/100,000. Although most cases are idiopathic, 15-30% of all cases of adult-onset DM represent a paraneoplastic syndrome caused by a concurrent malignancy [2]. Although rare, in cancer patients DM has also been described as a possible adverse event (AE) of certain classes of antineoplastic agents.

Paclitaxel is an antimetabolic drug widely used for the treatment of various types of malignant diseases and is frequently used in first-line regimens in breast cancer patients [3]. This drug is well known for frequent neurological and cutaneous toxicities, although grade three or higher AEs are rare [4]. Trastuzumab and pertuzumab are humanized monoclonal antibodies against human epidermal growth factor receptor 2 (HER2) used to treat HER2-positive breast cancers. Trastuzumab is more frequently linked to cardiotoxicity even as cutaneous toxicities have already been reported [3]. Herein, we report a 35-year-old woman with metastatic breast cancer who presented with DM skin lesions after initiation of paclitaxel and anti-HER2 drugs.

Case Synopsis

A 35-year-old premenopausal woman presented with a palpable nodule in her left breast on self-examination. She had no personal or family history of known diseases. Mammography and mammary

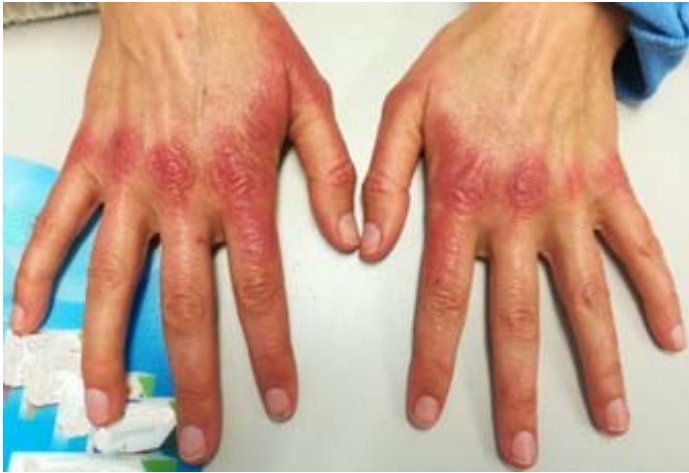

Figure 1. Dermatomyositis: characteristic erythematous flat-topped papules over metacarpophalangeal and proximal interphalangeal joints. These lesions emerged 6 weeks after the beginning of cytotoxic treatment.

magnetic resonance imaging (MRI) showed a 9×7×4.5cm mass in the upper-outer quadrant of the left breast and left axillary adenopathy (15mm of major axis). A core needle biopsy was performed, confirming the diagnosis of a grade two ductal carcinoma no special type (NST), estrogen and

progesterone receptors positive (HR+), HER2/Neu positive (3+), and a Ki67 of 30%. A computed tomography scan of the chest, abdomen, and pelvis showed enlarged left axillary lymph nodes with no evidence of distant disease. Additional bone scintigraphy revealed multiple bone metastasis in the lumbar spine, rib cage, sacral wings, and iliac bones. She was referred to our oncology outpatient clinic for further evaluation and management.

The patient started first line chemotherapy (ChT) with weekly paclitaxel (80 mg/m²) and pertuzumab plus trastuzumab every three weeks with palliative intent (adapted CLEOPATRA trial regimen [5]). An acneiform rash involving the anterior cervical and thoracic regions was reported one week after the first cycle of ChT, which was initially interpreted as a skin toxicity related to paclitaxel. She was treated with topical betamethasone with only slight improvement in the following weeks. Six weeks after the beginning of ChT the patient presented to our clinic with de novo cutaneous erythematous eruptions on both hands (**Figure 1**), with acroparesthesia, arthralgia, and pruritus of the dorsal face of both hands. Other signs and symptoms were absent, including rash or arthralgia in any other topography, weakness of the upper and lower limbs, dysphagia, respiratory complaints, or constitutional symptoms. Due to the characteristic pattern of the

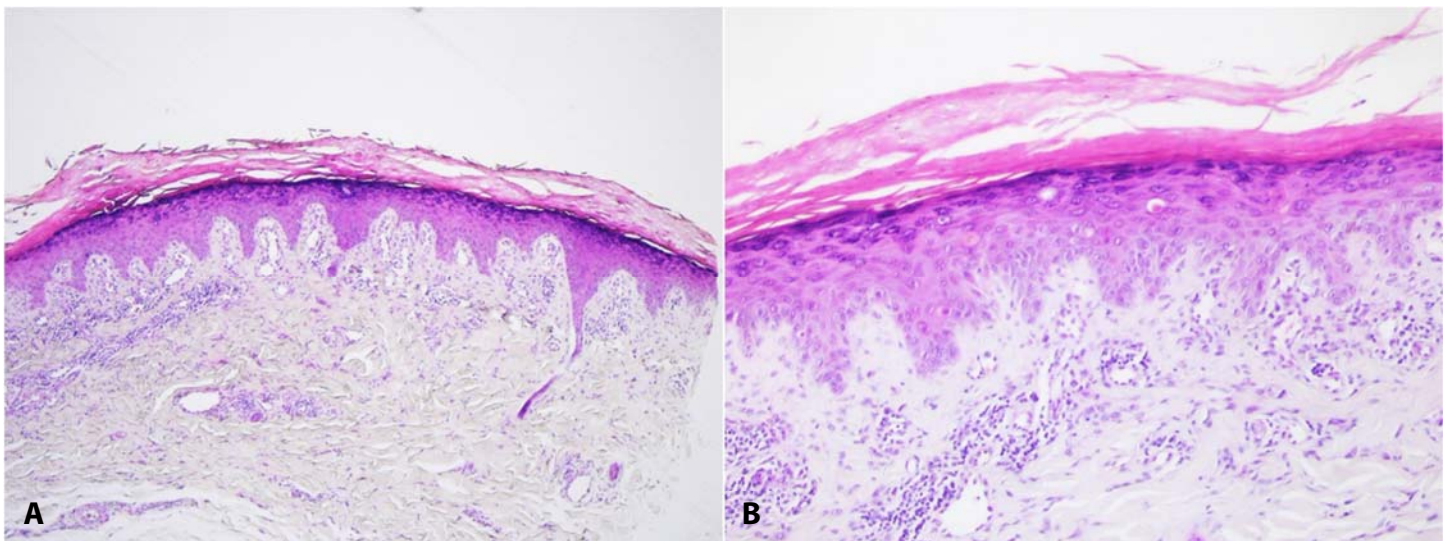


Figure 2. Gottron papule. H&E histology from skin biopsy shows features of a lichenoid tissue reaction consisting of focal vacuolar change in the basal layer, with numerous apoptotic keratinocytes, along with thickening of the basement membrane. Also, there is an irregular epidermal acanthosis with hypergranulosis and mild compact orthokeratotic hyperkeratosis. In the papillary dermis, along the dermo-epidermal junction and around superficial telangiectatic vessels, there is a sparse lymphohistiocytic inflammatory infiltrate, with neither eosinophils, nor neutrophils. **A)** 40×; **B)** 100×.

dermatologic lesions the hypothesis of DM was considered.

The patient was initially medicated with oral corticosteroids (prednisone, 20mg daily), topical clobetasol propionate, and a urea-based cream for the affected skin area. Blood tests were performed showing increased levels of aldolase (19.9U/L; range 1.0-7.5U/L), lactate dehydrogenase (LDH 633U/L; range 100-250U/L), aspartate aminotransferase (AST 65U/L; range 0-40U/L) and alanine aminotransferase (ALT 182U/L; range 0-41U/L). Antinuclear antibodies and anti-PL7 were strongly positive. The remaining myositis-specific antibodies and myositis-associated antibodies were negative. Other laboratory tests were unremarkable. A skin biopsy was taken from the left hand and the histopathological analysis was consistent with Gottron papules (**Figure 2**). The patient was referred to the dermatology and rheumatology clinic of our center and the diagnosis of DM was assigned. Accordingly, she started treatment with hydroxychloroquine and maintained systemic prednisone.

The patient completed a total of four cycles of paclitaxel and pertuzumab plus trastuzumab and later started a subsequent regimen of ChT free of taxanes and HER2 blockade. Progressive improvement of skin lesions and concomitant arthralgia and pruritus was observed. Descending levels of LDH, AST and ALT were observed in subsequent blood tests. Since then, no relapse of DM symptoms was reported and six months later the patient remains free of symptoms without any further intervention.

Case Discussion

This female patient without relevant past personal history and recent diagnosis of metastatic breast cancer developed features of DM after starting a treatment regimen composed of an antimitotic agent and two humanized monoclonal antibodies against HER2.

The connection between autoinflammatory connective tissue disorders and cancer is well established. Dermatomyositis is an idiopathic

inflammatory myopathy characterized by skin rash and myopathy of variable degrees [6]. Although most cases are idiopathic, approximately 15 to 30% of adult-onset DM represent with a paraneoplastic syndrome caused by a concurrent malignancy, most commonly lung, ovarian, and breast cancer [1,6,7]. The mechanisms behind this association are not fully clear. A proposed hypothesis is that shared antigen expression between regenerating myocytes and cancer cells might trigger an inflammatory response, which is the basis for the development of the autoimmune disease [8]. In our patient, the DM diagnosis was determined based on cutaneous manifestations, histologically-confirmed Gottron papules on skin biopsy, increased aldolase, AST and LDH, and PL7 positivity.

Dermatomyositis features only emerged after the breast cancer diagnosis and even worsened during antineoplastic treatment. Paraneoplastic DM typically show an improvement of symptoms upon initiation of treatment for the underlying malignancy and many authors report complete remission of DM manifestations after cancer regression. However, it has been widely reported that some cases of paraneoplastic dermatomyositis do not show symptomatic improvement after initiation of antineoplastic treatment and still require long-term immune suppression. Additionally, symptoms of paraneoplastic DM can emerge both before and after cancer diagnosis. It is true that our patient's symptoms improved after switching to a different chemotherapeutic regimen, but this happened contemporaneously with initiation of hydroxychloroquine and prednisone. Subsequent and progressive symptomatic improvement along with the descending levels of LDH, AST, and ALT after prednisone and hydroxychloroquine treatment, are in line with what would be expected in a paraneoplastic DM.

The possibility of a paraneoplastic DM should always be considered, as the presence of a pathophysiological link between DM and the cancer is very probable. Anti-PL7 antibody positivity is worthy of discussion. Transcriptional intermediary factor one gamma (Anti-TIF1 γ anti-p155, anti-p155/140), is the most commonly found antibody in

paraneoplastic DM, with a rate of associated malignancy ranging from 60-80% [6]. Additionally, the presence of nuclear matrix protein 2 (Anti-NXP2) is also considered an important cancer risk factor in adult patients, since 30% of DM patients positive for Anti-NXP2 develop cancer during their lifetime. By contrast, anti synthetase autoantibodies (Anti-Jo1, Anti-PL7, Anti-PL12, Anti-EJ, Anti-OJ, Anti-KS, Anti-Ha, Anti-Zo), anti-Mi2, anti-SRP, and other myositis-associated antibodies (such as anti-RNP, anti-PM-Scl, anti-Ku) are not commonly associated with malignancy. Anti- PL7 is typically associated with increased risk for interstitial lung disease and anti-synthetase syndrome (ASS) rather than cancer, although rare cases of cancer-associated ASS have been published in the literature [9].

On the other hand, our patient's symptoms only developed after the start of paclitaxel, pertuzumab, and trastuzumab and significantly improved after discontinuation of these chemotherapy and anti-HER2 drugs together with initiation of corticosteroids and hydroxychloroquine. Interestingly, no symptom relapse was reported after initiation of a different chemotherapy regimen without taxanes and anti-HER2 drugs. Progressive clinical and laboratory improvements after discontinuation of taxane and anti-HER2 agents and treatment with prednisone and hydroxychloroquine are also in line with what would be expected in a drug-induced DM.

Paclitaxel is an antineoplastic drug that belongs to the taxane class of cytotoxic agents. It acts by promoting stabilization of microtubules, thus disrupting mitosis, and finally leading to cell death [10]. Dermatological AEs are frequently reported and most treated patients experience mild to moderate self-limiting symptoms. Severe AEs are mainly induced by a toxic and non-immunoallergic mechanism, sometimes requiring dose reduction or suspension of chemotherapy. Although more rare, both paclitaxel and docetaxel can induce skin lesions similar to several autoimmune diseases such as drug-induced lupus erythematosus, scleroderma-like skin lesions, and Raynaud phenomenon [10]. A few cases of taxane-induced DM are reported in the literature, all of them after docetaxel treatment [11]. One report

suggests worsening of DM cutaneous lesions upon initiation of paclitaxel treatment in a patient with metastatic breast cancer and paraneoplastic DM [2].

The underlying mechanisms of taxane-induced autoimmune skin reactions are still poorly understood. Both paclitaxel and docetaxel may promote the release of nucleosomes, leading to a secondary local autoimmune reaction [10]. Also, it is speculated that multiple inflammatory cytokines such as tumor necrosis factor (TNF), that may be either produced by cancer tissue itself or released by taxane inflamed tissues, may play an important role in the onset of DM cutaneous lesions [11].

Trastuzumab and pertuzumab are humanized monoclonal antibodies against HER2, widely used as standard treatment for HER2-positive breast cancer patients [3]. One mechanism of action of trastuzumab is through CD16-mediated antibody-dependent cellular cytotoxicity (ADCC). Trastuzumab stimulates CD16 on natural killer cells enhancing their cytotoxic response, thus stimulating the immune system against cancer cells [12]. Dermatomyositis is a rare AE of trastuzumab therapy that is scarcely reported in the literature. Two published case reports describe an association between trastuzumab treatment and DM, both in patients with breast cancer. Both describe patients that have developed symptoms compatible with DM after trastuzumab exposure and their resolution after its discontinuation [12,13].

In our patient, the possible drug-induced DM was more likely either triggered by a nucleosome-mediated auto-immune reaction induced by paclitaxel or by an ADCC mechanism induced by trastuzumab. It is difficult to ascertain which mechanism was dominant since symptoms resolved after both paclitaxel and trastuzumab discontinuation, together with the start of treatment with systemic prednisone and hydroxychloroquine.

It is not possible to know for certain the etiology of our patient's DM due to the presence of confounding findings. The chance of a multifactorial context, with a relative contribution of a paraneoplastic mechanism coupled with a contribution of a drug-induced mechanism also seems plausible.

Conclusion

We report a metastatic breast cancer patient with DM diagnosed after initiation of paclitaxel, pertuzumab, and trastuzumab treatment. Although dermatologic alterations are common AEs of taxanes, severe autoimmune drug-induced skin toxicities are rare. Anti-HER2 skin toxicities are seldom reported and DM as a side effect has been very scarcely mentioned in the literature. The underlying mechanisms of these associations are still poorly understood. Nonetheless, the initial presentation and course of the DM lesions in our patient may be explained by a paraneoplastic and/or

toxic etiology. The diagnosis of drug-induced DM is challenging as it may be confounded with a paraneoplastic syndrome or manifest as a constellation of symptoms similar to other and more frequent dermatologic toxicities. Clinicians should be aware of autoimmune manifestations associated with paraneoplastic syndromes and acknowledge that DM induced by antineoplastic drugs is a rarer but plausible event.

Potential conflicts of interest

The authors declare no conflicts of interest.

References

1. Wong DE, Williams E, Warrier S. Dermatomyositis Developing Post Neoadjuvant Chemotherapy and Lumpectomy. *R I Med J*. 2018;101:34-36. [PMID: 30068052].
2. Kim Y, Jung W, Park YH. Dermatomyositis and paclitaxel-induced cutaneous drug eruption associated with metastatic breast cancer. *J Breast Cancer*. 2015;18:195-199. [PMID: 26155297].
3. Gennari A, André F, Barrios CH, et al. ESMO Clinical Practice Guideline for the diagnosis, staging and treatment of patients with metastatic breast cancer. *Ann Oncol*. 2021;32:1475-1495. [PMID: 34678411].
4. Abu Samaan TM, Samec M, Liskova A, et al. Paclitaxel's Mechanistic and Clinical Effects on Breast Cancer. *Biomolecules*. 2019;9:1-22. [PMID: 31783552].
5. Swain SM, Miles D, Kim SB, et al. Pertuzumab, trastuzumab, and docetaxel for HER2-positive metastatic breast cancer (CLEOPATRA): end-of-study results from a double-blind, randomised, placebo-controlled, phase three study. *Lancet Oncol*. 2020;21:519-530. [PMID: 32171426].
6. Didona D, Fania L, Didona B, et al. Paraneoplastic dermatoses: A brief general review and an extensive analysis of paraneoplastic pemphigus and paraneoplastic dermatomyositis. *Int J Mol Sci*. 2020;21:1-15. [PMID: 32245283].
7. Bogdanov I, Kazandjieva J, Darlenski R, et al. Dermatomyositis: Current concepts. *Clin Dermatol*. 2018;36:450-458. [PMID: 30047429].
8. Krathen MS, Fiorentino D, Werth VP. Dermatomyositis. *Curr Dir Autoimmun*. 2008;10:313-332. [PMID: 18460893].
9. Kuga T, Abe Y, Matsushita M, et al. Analysis of 11 cases of anti-PL-7 antibody positive patients with idiopathic inflammatory myopathies. Malignancy may not be uncommon complication in anti-PL-7 antibody positive myositis patients. *Ann Reum Dis*; 2019; 78: 846. [DOI: 10.1136/annrheumdis-2019-eular.4150].
10. Sibaud V, Leboeuf NR, Roche H, et al. Dermatological adverse events with taxane chemotherapy. *Eur J Dermatology*. 2016;26:427-443. [PMID: 27550571].
11. Ito Y, Hamada Y, Katayama K, Uno H, Nakada T. Dermatomyositis Associated with Docetaxel Use in the Treatment for Ovarian Cancer. *Case Reports Clin Med*. 2017;06:281-284. DOI:10.4236/crcm.2017.610031
12. Trontzas IP, Syrigos NK, Kotteas EA. A case of trastuzumab-induced dermatomyositis. *J Can Res Ther*. 2021;17:1112-4. [PMID: 34528573].
13. Moghimi M, Khodadadi K. Dermatomyositis following Biosimilar Trastuzumab in a Breast Cancer Patient: A Case Report. *Case Rep Oncol*. 2021;14:1134-1138. [PMID: 34413744].