

# UC Davis

## Dermatology Online Journal

### Title

Recurrent angiolymphoid hyperplasia with eosinophilia during several pregnancies

### Permalink

<https://escholarship.org/uc/item/0131j1kh>

### Journal

Dermatology Online Journal, 26(8)

### Authors

Cenk, Hulya  
Kapicioglu, Yelda  
Sarac, Gulbahar  
et al.

### Publication Date

2020

### DOI

10.5070/D3268049890

### Copyright Information

Copyright 2020 by the author(s). This work is made available under the terms of a Creative Commons Attribution-NonCommercial-NoDerivatives License, available at <https://creativecommons.org/licenses/by-nc-nd/4.0/>

Peer reviewed

# Recurrent angiolymphoid hyperplasia with eosinophilia during several pregnancies

Hulya Cenk<sup>1</sup>, Yelda Kapicioglu<sup>2</sup>, Gulbahar Sarac<sup>3</sup>, Serpil Sener<sup>3</sup>, Nurhan Sahin<sup>4</sup>

Affiliations: <sup>1</sup>Malatya Training and Research Center, <sup>2</sup>Department of Dermatology, Liv Hospital, Istanbul, Turkey, <sup>3</sup>Inonu University, Department of Dermatology, Turgut Ozal Medical Center, Malatya, Turkey, <sup>4</sup>Department of Pathology, Bezmialem Vakif University, Istanbul, Turkey

Corresponding Author: Hulya Cenk, Department of Dermatology, Malatya Training and Research Hospital, Malatya 44100, Turkey, Tel: 90-5374374486, Fax: 90-4223253438, Email: [hulya86@msn.com](mailto:hulya86@msn.com)

## Abstract

Angiolymphoid hyperplasia with eosinophilia (ALHE) is a rare, benign vascular tumor. Although its etiology is not clearly known, infection, hormonal factors, and trauma are the suspected reasons. There are few cases considered to be related to pregnancy described in the literature. Granulomas are rarely seen in the histopathology and only four patients with granulomas have been described. Herein, we will present a 28-year-old woman who has been pregnant three times; in every pregnancy, she developed pink nodular lesions on the back of her ear. In the first two pregnancies, the lesions had appeared during the pregnancy and regressed completely in the postpartum period. In her third pregnancy, the condition emerged again and lasted 1.5 years after birth of her child. Histopathology exhibited ALHE with granulomas. Although the relationship between ALHE and pregnancy is already known, there are few cutaneous ALHE cases associated with pregnancy reported in the literature. This association is further supported by this case having recurrent ALHE during each pregnancy period. Also, the presence of naked granuloma in histopathology, unlike most of the cases, contributes to the current histopathological data.

*Keywords: angiolymphoid hyperplasia, eosinophilia, granuloma, pregnancy, vascular tumor, estrogen, progesterone, oral contraceptive*

## Introduction

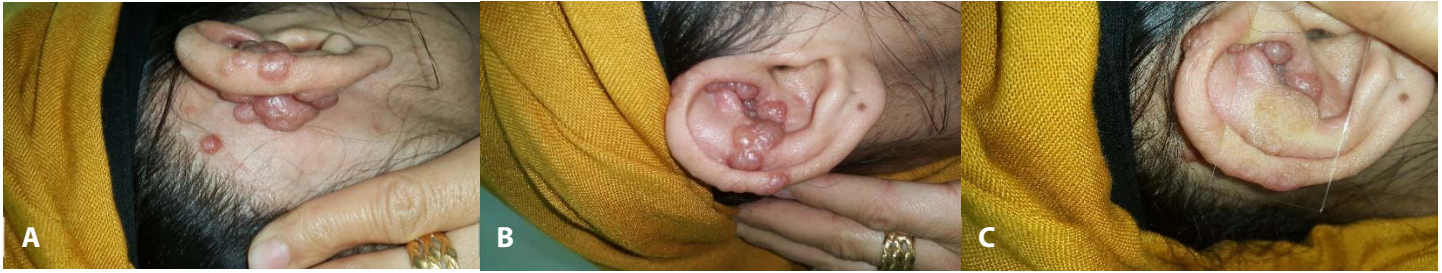Angiolymphoid hyperplasia with eosinophilia (ALHE) is a rare, benign vascular tumor. It is often seen in the

head and neck area as reddish-brown papules and nodules [1,2]. Although its etiology is not fully known, infection, trauma, hormonal factors like hyperestrogenemia (pregnancy or oral contraceptive use), infectious agents, and atopy have been associated. Reactive hyperplasia and benign neoplasia have both been postulated [3,4]. Granulomas are rarely seen in the histopathology; four cases have been reported as far as we know [5-8]. A small number of pregnancy-associated cases have been described [3,7,9-13].

A 28-year old mother of three children has presented to our clinic with the complaints of relapsing nodules on the back of her ear. The nodules appeared during the last trimester of her pregnancies. The last lesions had persisted 1.5 years after the third pregnancy. The biopsy result was consistent with ALHE, and interestingly, there were granulomas present. Herein, we will discuss ALHE and the relationship with hormonal factors and ALHE histopathology.

## Case Synopsis

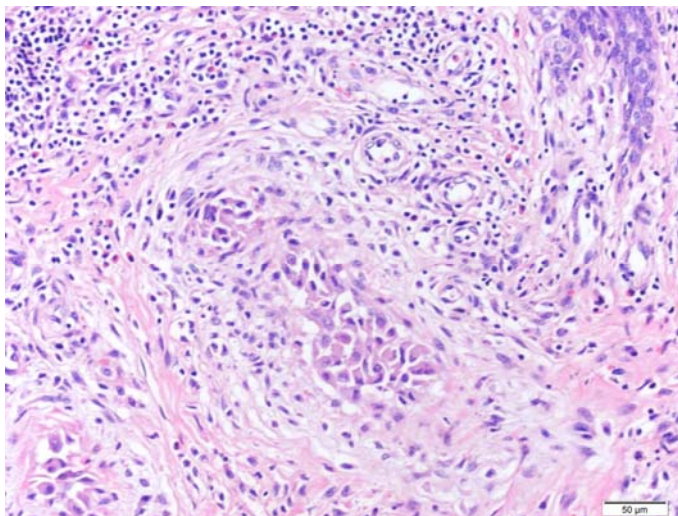
A 28-year-old woman presented to our clinic with the complaints of itchy, pinkish masses on her right ear for the last 1.5 years. There were some pink, violaceous, and skin-colored grouped nodules on the back of the ear and there was a solitary, pink, partially translucent papule near the proximal hairline. Similar lesions were present on the lateral and anterior ear helix and the apple-jelly sign was positive on diascopy (**Figure 1**). Regional lymph node examination was normal. The first lesions had started at the 9<sup>th</sup> month of the first pregnancy 7 years



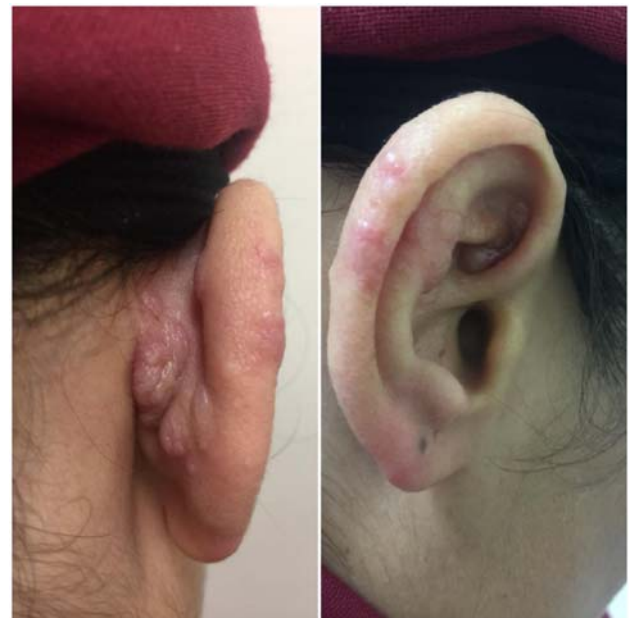**Figure 1.** A solitary, pink, 1 cm diameter papule near the proximal hairline and similar heterogeneous papules behind the ear. **B)** Lateral and anterior ear helix lesions. Some are solitary or grouped, pink-violet papulonodules with heterogeneous color. **C)** Apple jelly sign on diascopic examination.

prior and they disappeared one month after delivery. The lesions had emerged again at the 8<sup>th</sup> month of the second pregnancy and spontaneously regressed two months after delivery. Lastly, the nodules emerged again on the 7<sup>th</sup> month of the third pregnancy and have lasted for the last 1.5 years. Her medical and family history was unremarkable.

A biopsy was performed with preliminary diagnoses of trichoepithelioma, cylindroma, T-cell lymphoma, cutaneous B-cell lymphoma, sarcoidosis, B-cell pseudolymphoma, juvenile hyaline fibrosis, ALHE, angiosarcoma, and lupus vulgaris were all considered. The biopsy revealed an onion-skin appearance around the vessels with papillary endothelial proliferation resembling naked granulomas and these structures were surrounded by eosinophil-rich inflammatory cell infiltration (**Figure 2**). The patient was diagnosed with ALHE from the clinicohistopathological aspect and intralesional triamcinolone acetonide (20mg/ml)



**Figure 2.** Granulomatous structures consisting of inflammatory cells and histiocytes. H&E, 200x.



**Figure 3.** Seventy percent clearance of the lesions with systemic corticosteroid and intralesional corticosteroid injections.

injection and topical tacrolimus treatments were started. She has received three injections monthly. The response was not fully satisfactory. She exhibited a poor response to methylprednisolone, but when indomethacin was added she responded well within three months (**Figure 3**). However, she stopped both treatments because of unacceptable side effects. Lastly, the patient received 577nm Pro-Yellow laser treatment (QuadroStarPRO YELLOW® Asclepion Laser Technologies, Germany) at 4-week intervals in three consecutive sessions at 20, 22 and 24J/cm<sup>2</sup>, and resulted in clearance almost completely (**Figure 4**).

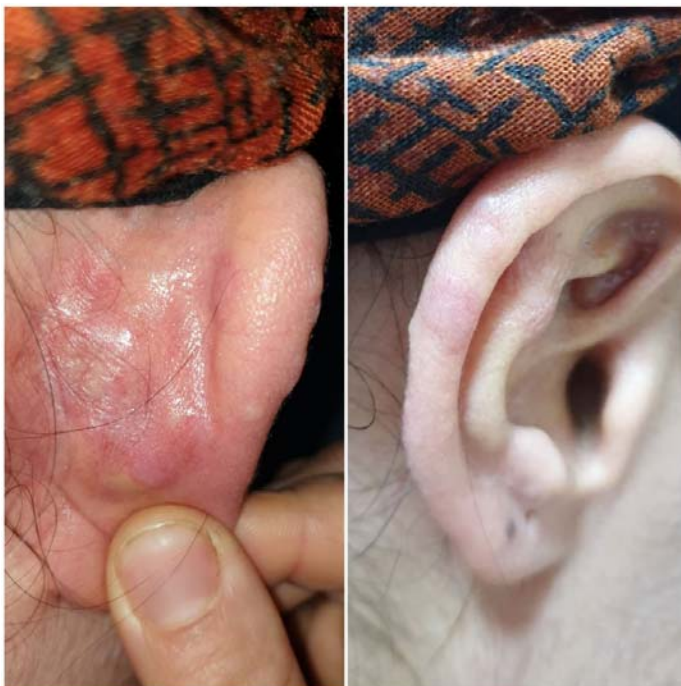### Case Discussion

Angiolymphoid hyperplasia with eosinophilia is a benign vascular tumor, which is often seen in adults,



mostly women. It is characterized by skin-colored or reddish-brown papules and nodules mostly in the head and neck region [1,2]. It can be symptomatic, and bleeding, itching, and sensation of pulsation are common features of ALHE [2,13]. In our case, there were itchy papules heterogeneous in color and the apple-jelly sign was positive on diascopic examination.

Although the etiology is not fully known, there are some cases in the literature indicating a positive relationship between ALHE and birth control pills or pregnancy. Some patients had used birth control pills, some of them had used birth control pills prior to onset of pregnancy, and some had only a pregnancy history [10-14]. Moy et al. showed increased levels of estrogen and progesterone receptors in the lesional skin compared to the non-lesional skin of two patients [10]. Damarla et al. have indicated that hyperestrogenic states and increased levels of estrogen and progesterone receptors in the lesions during pregnancy may have a role in the occurrence or aggravation of ALHE lesions. They have also indicated that estrogens may have an indirect role in ALHE etiopathogenesis without any overexpression of estrogen and progesterone receptors [9]. Our patient had three pregnancies and



**Figure 4.** Approximately 90 % clearance of the lesions with Pro-Yellow laser treatment.

recurrent lesions in the last trimester of each pregnancy. Since she had resolution periods between the pregnancies, we believe that the hormonal status in the pregnancies may be an etiologic factor in the ALHE in accordance with the literature.

Histopathologically; there were swollen endothelial cells, proliferative blood vessels, lymphoid follicles, lymphocytes in perivascular and interstitial areas, and infiltration with plasma cells and eosinophils [2,7]. In our case, some structures resembling a naked granuloma were also observed in the biopsy. Clinically, the diascopic examination also showed a positive apple jelly sign suggestive of a granulomatous reaction. To our knowledge, this case is the fourth case of ALHE with granuloma; this finding was first reported in detail by Sakamoto et al. in 1998. They have defined two types of granulomas: the osteoclastic type and the giant cell type in which the nuclei are lined like a wreath in the periphery [7]. Castro et al. also showed a Touton-type giant cell [5]. Finally, an ALHE case with a histiocytic giant cell was published by Kaur et al. in 2016 [6].

The entities in the differential diagnosis in the literature includes Kimura disease, other vascular and reactive lymphoid conditions, Langerhans cell histiocytosis, and granulomatous infections [7,8]. Clinically, we considered trichoepithelioma, cylindroma, T and B-cell lymphoma, sarcoidosis, pseudolymphoma, juvenile hyaline fibrosis, ALHE, and angiosarcoma. Some of these diagnoses may be excluded by history or clinically, but most may be excluded histopathologically.

Besides, ALHE sometimes regresses spontaneously. Treatment options include intralesional corticosteroid injection, cryotherapy, laser, surgery, oral corticosteroids, topical imiquimod, tacrolimus, indomethacin, methotrexate, and topical timolol [1,2,11,15,16]. In our case, after poor response to topical tacrolimus and intralesional corticosteroid injection treatments, the patient had started oral methylprednisolone, which gave unsatisfactory results until oral indomethacin was added, based on the report of Noumra et al. [11]. Afterwards the patient experienced relatively rapid improvement

but unacceptable side effects. Laser therapy produced excellent improvement.

## Conclusion

Although there are few cases reported, the relationship between pregnancy and ALHE is reported in the literature. A hormonal hypothesis of etiology is supported further by this patient in whom

ALHE lesions emerged over and over again in each pregnancy period. Also, naked granuloma-like structures in the histopathology make the case more unusual.

## Potential conflicts of interest

The authors declare no conflicts of interests.

## References

1. Guo R, Gavino ACP. Angiolymphoid Hyperplasia With Eosinophilia. *Arch Pathol Lab Med.* 2015;139:683-686. [PMID: 25927152].
2. Zarrin-Khameh N, Spoden JE, Tran RM. Angiolymphoid Hyperplasia With Eosinophilia Associated With Pregnancy: A Case Report and Review of the Literature. *Arch Pathol Lab Med.* 2005;129:1168-1171. [PMID: 16119993].
3. Hollo P, Marschalko M, Sikos G, Harsing J, Horvath A. Angiolymphoid hyperplasia with eosinophilia in pregnancy. *J Eur Acad Dermatol Venereol.* 2005;19:645-646. [PMID: 16164732].
4. Adler BL, Krausz AE, Minuti A, Silverberg JI, Lev-Tov H. Epidemiology and treatment of angiolymphoid hyperplasia with eosinophilia (ALHE): A systematic review. *J Am Acad Dermatol.* 2016;74:506-12.e11. [PMID: 26685720].
5. Castro C, Winkelmann RK. Angiolymphoid hyperplasia with eosinophilia in the skin. *Cancer.* 1974;34:1696-1705. [PMID: 4371945].
6. Kaur M, Dalal V, Ramesh V, Singh A. Multinucleated giant cells in angiolymphoid hyperplasia with eosinophilia. *Indian J Dermatol Venereol Leprol.* 2016;82:567-569. [PMID: 27241504].
7. Macarenco RS, do Canto AL, Gonzalez S. Angiolymphoid Hyperplasia With Eosinophilia Showing Prominent Granulomatous and Fibrotic Reaction: A Morphological and Immunohistochemical Study. *Am J Dermatopathol.* 2006;28:514-517. [PMID: 17122496].
8. Sakamoto F, Hashimoto T, Takenouchi T, Ito M, Nitto H. Angiolymphoid hyperplasia with eosinophilia presenting multinucleated cells in histology: an ultrastructural study. *J Cutan Pathol.* 1998;25:322-326. [PMID: 9694622].
9. Damarla S, S. Chintagunta, and G. Arakkal, Recurrent unilateral angiolymphoid hyperplasia with eosinophilia in pregnancy. *Indian J Dermatol Venereol Leprol.* 2018;84: p. 325-327. [PMID: 29620039].
10. Moy RL, Luftman DB, Nguyen QH, Amenta JS. Estrogen receptors and the response to sex hormones in angiolymphoid hyperplasia with eosinophilia. *Arch Dermatol.* 1992;128:825-828. [PMID: 1599273].
11. Nomura K, Sasaki C, Murai T, Mitsuhashi Y, Sato S. Angiolymphoid hyperplasia with eosinophilia: successful treatment with indomethacin farnesil. *Br J Dermatol.* 1996;134:189-190. [PMID: 8745919].
12. Olsen TG, Helwig EB. Angiolymphoid hyperplasia with eosinophilia. A clinicopathologic study of 116 patients. *J Am Acad Dermatol.* 1985;12:781-796. [PMID: 4008683].
13. Parimalam K, Thomas J. Angiolymphoid hyperplasia with eosinophilia associated with pregnancy - A rare report. *Indian J. Dermatol.* 2016;61:125-125. [PMID: 26955154].
14. Theofilou NE, Scolozzi P, Lombardi T. Angiolymphoid Hyperplasia with Eosinophilia Located on the Forehead: A Possible Association with Oral Contraceptive Use? *Dermatopathology (Basel).* 2019;12:6:225-230. [PMID: 31828064].
15. Alaidarous A, Bouissou X, Mazereeuw-Hautier J, Bulai-Livideanu C, Lamant L, et al. Angiolymphoid hyperplasia with eosinophilia treated with low-dose methotrexate. *JAAD Case Rep.* 2015;27:1:342-4. [PMID: 27051774].
16. Arora P, Meena N, Sharma PK, Bhardwaj M. Angiolymphoid Hyperplasia with Eosinophilia and its Response to the Combination of Radiofrequency Ablation and Topical Timolol. *Indian Dermatol Online J.* 2017;8:267-270. [PMID: 28761845].