

# UC Davis

## Dermatology Online Journal

### Title

Cutaneous rhabdomyoma in an 82-year-old White man

### Permalink

<https://escholarship.org/uc/item/47s2q8zk>

### Journal

Dermatology Online Journal, 29(3)

### Authors

Casale, Jarett  
Uddin, Sabiha  
Upchurch, Britton  
et al.

### Publication Date

2023

### DOI

10.5070/D329361429

### Copyright Information

Copyright 2023 by the author(s). This work is made available under the terms of a Creative Commons Attribution-NonCommercial-NoDerivatives License, available at <https://creativecommons.org/licenses/by-nc-nd/4.0/>

Peer reviewed

# Cutaneous rhabdomyoma in an 82-year-old White man

Jarett Casale<sup>1</sup> DO, Sabiha Uddin<sup>2</sup> BS, Britton Upchurch<sup>2</sup> BS, Muammar Arida<sup>1</sup> MD, Adam Ingraffea<sup>3</sup> MD

Affiliations: <sup>1</sup>Sampson Regional Medical Center, Campbell University, Clinton, North Carolina, USA, <sup>2</sup>Campbell University School of Osteopathic Medicine, Lillington, North Carolina, USA, <sup>3</sup>Cary Skin Center, Cary, North Carolina, USA

Corresponding Author: Jarett Casale DO, Sampson Regional Medical Center, Campbell University, 607 Beaman Street, Clinton, NC 28328, Tel: 919-389-9293, Email: [jjcasale0410@Email.campbell.edu](mailto:jjcasale0410@Email.campbell.edu)

## Abstract

This case highlights a primary cutaneous rhabdomyoma presenting as a slowly enlarging subcutaneous nodule on the mentum of an 82-year-old White man with a medical history of two intracranial rhabdomyomas. Although they are rarely syndromic, it is important to note that the most common demographic for presentation of rhabdomyomas includes older males presenting as a subcutaneous nodule on the head, neck, or oral cavity. They are most often seen in isolation but can be multifocal in up to 25% of all cases. Being a rare entity, there is no generally recognized treatment consensus; however, complete surgical excision is recommended to prevent recurrence and morbidity from local tissue destruction.

*Keywords: cardiac, cutaneous, excision, mesenchymal, muscle, neoplasm, rhabdomyoma, skeletal, striated*

## Introduction

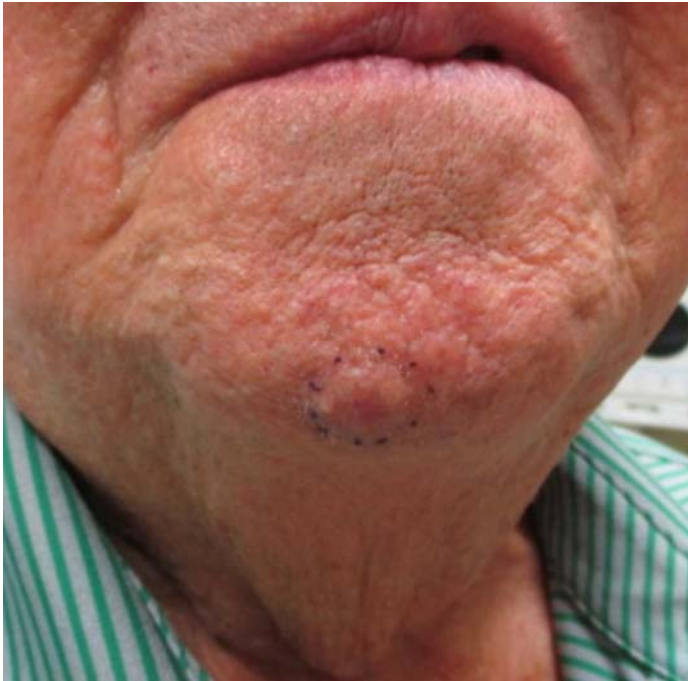Rhabdomyomas are benign mesenchymal tumors composed of skeletal muscle that are classified as either cardiac or extracardiac. Cardiac rhabdomyomas have a prevalence of 0.09% in children and are typically associated with various neurocutaneous congenital disorders, such as tuberous sclerosis [1,2]. Compared to cardiac rhabdomyomas, extracardiac rhabdomyomas are considered as true neoplasms and are subdivided into three types: adult, fetal, and genital types. Adult-type rhabdomyomas are the most frequent among the extracardiac subtypes and typically present as a

solitary lesion, but up to 15% of cases can be multicentric [1,3]. This type of rhabdomyoma is commonly seen in elderly men with a predilection for the head and neck.

We present an elderly patient with a slowly enlarging subcutaneous nodule on the inferior mentum that was diagnosed as a cutaneous rhabdomyoma by punch biopsy. Conservative complete excision was recommended by pathology to evaluate the entire lesion. The patient subsequently underwent complete surgical excision with marginal evaluation. Although isolated rhabdomyomas are benign, excision is often recommended to prevent local tissue destruction and morbidity related to local invasion and neurovascular compromise.

## Case Synopsis

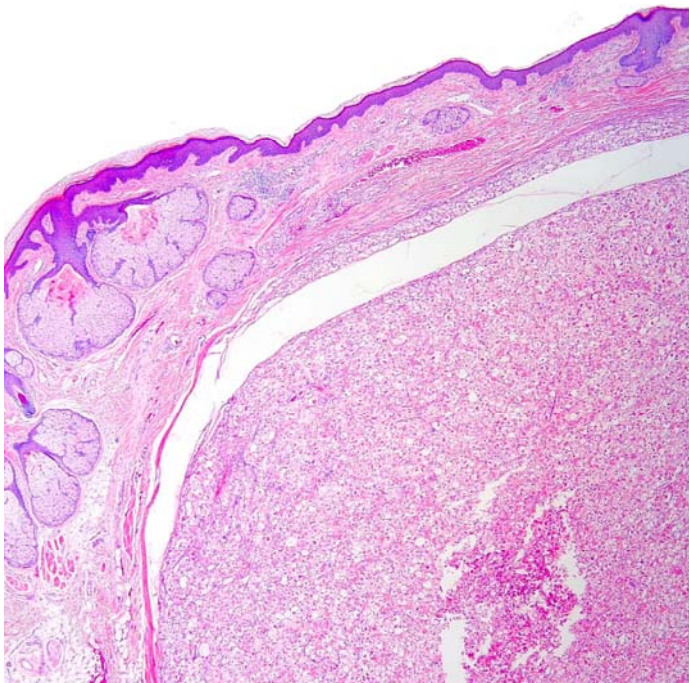
An 82-year-old White man presented to the clinic for an asymptomatic, slowly enlarging subcutaneous mass on his mentum (**Figure 1**). Past medical history was significant for two intracranial rhabdomyomas, as well as multiple nonmelanoma skin cancers on the bilateral arms and legs. The intracranial rhabdomyomas were identified on computerized tomography imaging after the patient presented with right-sided hearing loss worsening over the previous 10 years. He subsequently underwent a biopsy in 2006, which confirmed the diagnosis of intracranial rhabdomyoma. Treatment was opted against, given the risks of intracranial tumor removal and indolent growth pattern of the neoplasm. He does note 80% loss of auditory function in his right ear, for which he wears a hearing aid. He denies any



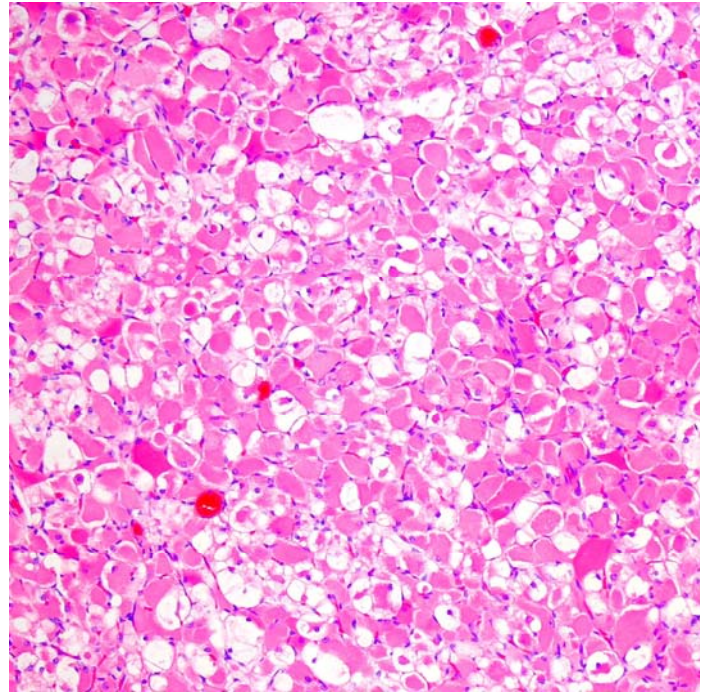
**Figure 1.** Clinical image of a rhabdomyoma as a skin-colored subcutaneous nodule on the mentum.

family history of tuberous sclerosis complex or other isolated rhabdomyomas.

A punch biopsy of the subcutaneous nodule on the patient's chin was performed, which revealed a diagnosis of cutaneous rhabdomyoma with involvement of the base of the biopsy specimen



**Figure 2.** H&E histopathology of the rhabdomyoma showing an encapsulated dermal proliferation of skeletal muscle fibers, 2x.

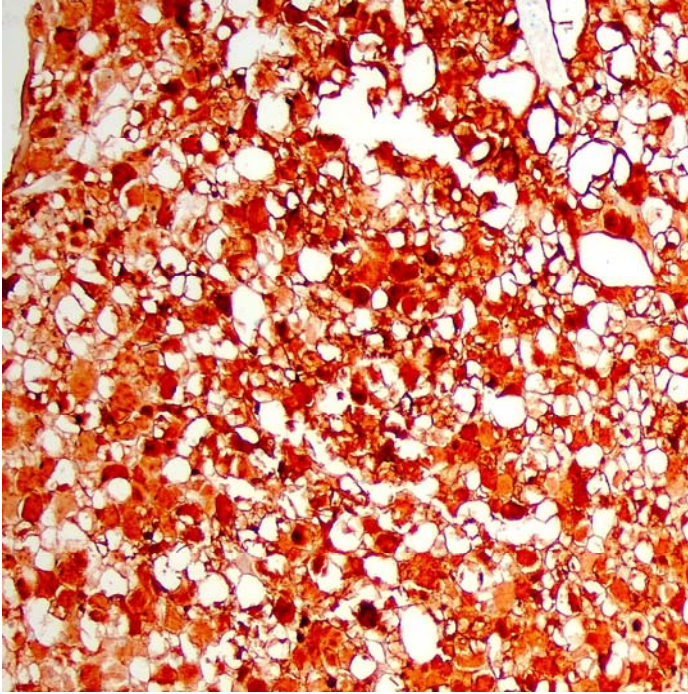


**Figure 3.** H&E histopathology of the rhabdomyoma showing a dermal proliferation of skeletal muscle fibers, 20x.

(**Figures 2, 3**). Immunohistochemical staining showed positivity for desmin and negative staining for S100, cytokeratin AE1/AE3, SMA, and Melan A (**Figure 4**). Conservative complete removal was recommended to evaluate the lesion in its entirety. The patient underwent conservative excision with 3mm margins, resulting in complete removal of the tumor and clear margins on histological examination. He was contacted for follow-up one year after excision and noted no evidence of tumor recurrence.

### Case Discussion

Rhabdomyomas are benign tumors of skeletal muscle differentiation. They are commonly seen as intracardiac tumors presenting in children before one year of age in association with congenital abnormalities, such as tuberous sclerosis. Cardiac rhabdomyomas are the most common pediatric heart tumor and are typically localized to the interventricular septum, ventricles, and/or the atrioventricular valves [4,5]. Extracardiac rhabdomyomas are much rarer than their cardiac counterparts and can be subdivided into adult, fetal, and genital types [6].



**Figure 4.** Positive immunohistochemical staining for desmin within the cells of the dermis in the rhabdomyoma. 20x.

Among extracardiac rhabdomyomas, the adult subtype is most common and tend to develop as painless, slow-growing, solitary masses in the head and neck region. These tumors are believed to originate from the branchial musculature and have a recurrence rate of 42% if not completely excised [6]. Adult rhabdomyomas most commonly present in elderly men, with a median age of 60 years old. Due to these tumors commonly presenting in the parapharyngeal space, dysphagia or hoarseness are often presenting symptoms [1]. As of 2021, there have been 33 cases of multifocal adult rhabdomyomas reported in the literature, all within the head and neck region and without cutaneous presentation [3].

Fetal extracardiac rhabdomyomas are exceedingly rare and share a predilection for the head and neck region of males, with a mean age of presentation at 2.1 years old. They present nearly identically to their adult counterparts as well circumscribed, mobile, non-painful nodules, but have a different histological presentation [7,8]. Adult rhabdomyomas are characterized histologically by the proliferation of large polygonal cells with eosinophilic cytoplasm, small nuclei, and uniform nucleoli. The cytoplasm of these cells may contain cross-striations or may be

vacuolated [8,9]. These cells represent mature skeletal muscle cells, which can be confirmed by positive immunohistochemical staining for desmin, muscle specific antigen, and myoglobin [6]. Histological differences in fetal rhabdomyomas include irregular bundles of immature skeletal muscles with a myxoid background and similar immunohistochemical profile [8]. In both adult and fetal rhabdomyomas, positive markers for S100 and smooth muscle actin have been observed, while negative markers include glial fibrillary acidic protein, cytokeratin, epithelial membrane antigen, and CD68, along with a low Ki67 mitotic index [8]. Histological examination of these lesions is exceedingly important to evaluate for the presence of cellular atypia and mitoses that may suggest a diagnosis of rhabdomyosarcoma, which is surprisingly more common than its benign counterpart [3].

A standardized treatment algorithm for cutaneous rhabdomyomas has not been elucidated due to the rarity of these lesions. In one case of fetal cutaneous rhabdomyoma, surgical excision was recommended due to cosmetic concerns and complete histological examination to rule out well-circumscribed rhabdomyosarcoma, while another case opted for close clinical monitoring [7,10]. The literature suggests that small, asymptomatic adult cutaneous rhabdomyomas can typically be clinically monitored, however, surgical excision with marginal evaluation is often recommended to prevent morbidity related to growth and compression of underlying neurovascular structures [3].

## Conclusion

This case highlights a rare multifocal rhabdomyoma presentation, including both intracranial and cutaneous neoplasms. It is important for dermatologists to be aware of the various presentations of rhabdomyomas, which can be cutaneous in nature as evidenced by this case. Histological evaluation is used to confirm the diagnosis of rhabdomyoma and helps differentiate it from malignant histological mimics, such as cutaneous rhabdomyosarcoma. Complete excision is

typically used to treat rhabdomyoma to provide symptom resolution, preserve neurovascular structures, and maintain the cosmetic appearance of the patient.

## References

1. de Trey LA, Schmid S, Huber GF. Multifocal adult rhabdomyoma of the head and neck manifestation in 7 locations and review of the literature. *Case Rep Otolaryngol*. 2013;2013:758416. [PMID: 23841004].
2. Freedom RM, Lee KJ, MacDonald C, Taylor G. Selected aspects of cardiac tumors in infancy and childhood. *Pediatr Cardiol*. 2000;21:299-316. [PMID: 10865003].
3. Khalaf MG, Haddad R, Akiki M, Khazen J, Melkane AE. Multifocal adult rhabdomyoma of the head and neck: case report and systematic review of the literature. *Int J Oral Maxillofac Surg*. 2021;50:327-334. [PMID: 32773112].
4. Bosi G, Lintermans JP, Pellegrino PA, Svaluto-Moreolo G, Vliers A. The natural history of cardiac rhabdomyoma with and without tuberous sclerosis. *Acta Paediatr*. 1996;85:928-31. [PMID: 8863873].
5. Beghetti M, Gow RM, Haney I, et al. Pediatric primary benign cardiac tumors: a 15-year review. *Am Heart J*. 1997;134:1107-14. [PMID: 9424072].
6. Hansen T, Katenkamp D. Rhabdomyoma of the head and neck: morphology and differential diagnosis. *Virchows Arch*. 2005;447:849-54. [PMID: 16133368].
7. Walsh SN, Hurt MA. Cutaneous fetal rhabdomyoma: a case report and historical review of the literature. *Am J Surg Pathol*. 2008;32:485-91. [PMID: 18300799].
8. Bridge JA, Hogendoorn P. In: WHO Classification of Tumours of Soft Tissue and Bone. Fletcher CDM, Bridge JA, Hogendoorn PCW, editors. International Agency for Research on Cancer. 2013. p. 123-136.
9. Kapadia SB, Meis JM, Frisman DM, et al. Adult rhabdomyoma of the head and neck: a clinicopathologic and immunophenotypic study. *Hum Pathol*. 1993;24:608-17. [PMID: 8505039].
10. Bardawil T, El Jamal L, Abbas O, Kurban M. Tuberous sclerosis with two unusual findings: cutaneous rhabdomyoma and chronic myelogenous leukaemia. *Clin Exp Dermatol*. 2020;45:799-801. [PMID: 32097503].

## Potential conflicts of interest

The authors declare no conflicts of interest.