

# UC Davis

## Dermatology Online Journal

### Title

Clinical features of atypical presentations of mucocutaneous herpes simplex virus infection observed in immunosuppressed individuals. Part I: herpetic geometric glossitis

### Permalink

<https://escholarship.org/uc/item/0k50k873>

### Journal

Dermatology Online Journal, 30(1)

### Author

Cohen, Philip R

### Publication Date

2024

### DOI

10.5070/D330163280

### Copyright Information

Copyright 2024 by the author(s). This work is made available under the terms of a Creative Commons Attribution-NonCommercial-NoDerivatives License, available at <https://creativecommons.org/licenses/by-nc-nd/4.0/>

Peer reviewed

# Clinical features of atypical presentations of mucocutaneous herpes simplex virus infection observed in immunosuppressed individuals. Part I: herpetic geometric glossitis

Philip R Cohen<sup>1,2</sup> MD

Affiliations: <sup>1</sup>Department of Dermatology, University of California Davis Health, Sacramento, California, USA, <sup>2</sup>Touro University California College of Osteopathic Medicine, Vallejo, California, USA

Corresponding Author: Philip R Cohen MD, 10991 Twinleaf Court, San Diego, CA 92131, Email: [mitehead@gmail.com](mailto:mitehead@gmail.com)

## Abstract

Herpetic geometric glossitis is a unique morphologic variant of HSV (herpes simplex virus) type 1 infection on the dorsum of the tongue that presents as an extremely painful linear central lingual fissure with a branched pattern in the center of the tongue; there is a branched pattern of fissures that extend bilaterally from the central linear fissure. Herpetic geometric glossitis has been reported in 11 patients; 8 of these individuals were immunocompromised. Medical conditions and immunosuppressive medication treatment (7 patients) or only medical disorders (3 patients) or neither (1 patient) were present. HSV type 1 infection was diagnosed by viral culture in (7 patients), Tzanck preparation (2 patients) or clinically (2 patients). Mucocutaneous HSV infection at non-lingual locations—including the lips, labial mucosa, face and chest—were observed in 5 patients. All patients' symptoms and lesions responded to treatment with oral antiviral therapy: acyclovir (9 patients), famciclovir (1 patient) or valacyclovir (1 patient). The lingual pain and dorsal tongue fissures completely resolved completely within two to 14 days. In summary, herpetic geometric glossitis is a unique HSV type 1 infection, usually in immunocompromised patients, that occurs on the dorsal tongue and responds completely after treatment with orally administered antiviral therapy.

*Keywords: branched, fissure, herpes, herpetic, geometric, glossitis, immunocompromised, infection, linear, lingual, longitudinal, painful, simplex, tongue, virus*

## Introduction

Mucutaneous manifestations of herpes simple virus (HSV) infection, particularly in immunocompetent individuals, typically present with characteristic clinical lesions. The morphology of the skin and/or mucosal lesions usually appears as small, erythematous-based vesicles; eventually these primary lesions evolve into erosions or superficial ulcers and subsequently develop into dried eschars that are eventually are desquamated. However, in an immunosuppressed patient, the appearance of an HSV infectious lesion can be variable [1-4].

Herpetic geometric glossitis (HGG) is a unique morphologic manifestations of HSV type 1 infectious lesions most commonly—but not exclusively—occurring in immunocompromised patients. The history and the morphologic features of HGG are reviewed. In addition, the differential diagnosis of this variant of HSV infection is summarized [5-82].

## Discussion

Herpetic geometric glossitis is a distinctive lingual presentation of HSV infection. The exquisitely tender dorsal tongue classically presents with acquired branching fissures. The clinical manifestations of HGG completely resolve after treatment with orally administered antiviral therapy [5,7-11,13-15].

## History

The history of HGG is summarized in [Table 1](#) [5-15]. The first patients with HGG were seen by the Dermatology Consultation Service at Columbia-

Presbyterian Medical Center in New York between 1989 and 1992. All the individuals were HIV-positive and immunocompromised. The unique presentation of HSV infection observed on the tongues of the three men and two women had not previously been described. In 1993, the investigators reported their observation as a brief report in the *New England Journal of Medicine* and introduced the nomenclature for this atypical HSV infection variant which included the etiology (herpetic for HSV), the morphology (geometric to highlight the characteristic branching pattern), and the affected site (glossitis to emphasize the involvement of the tongue): HGG [5].

The next year, in 1994, a pair of letters-to-the-editor were published. The researchers elucidated that this pattern of HSV infection on the tongue was similar in appearance to the dendrite associated with HSV infection of the corneal epithelium. All concurred that, based on the similarity in morphology of the HSV infection at both mucous membranes, a common underlying mechanism of pathogenesis likely accounted for both HGG and corneal HSV dendrites [6,7].

In 1995, two additional immunosuppressed patients with HGG were reported. They included a man who was a solid organ transplant recipient and an HIV-positive woman [8]. Two years later, in 1997, HGG was described in a boy who had acute myelogenous leukemia [9].

More recently, HGG has been observed in immunocompetent individuals. In 2009, it was described in a woman with viral pneumonia [10]. Subsequently, in 2019, it was noted in an immunocompetent man with bronchiectasis and pneumonia after treatment with prednisolone was initiated [13]. Another immunocompetent woman with HGG was also reported in 2022 [15].

The medical literature also contains two immunocompromised patients who were reported to have HGG; however, careful evaluation of the papers demonstrated that they did not fulfill the clinical criteria for the diagnosis. The first patient was a man with acute myelogenous leukemia and ulcers—not fissures—on his tongue [11]. The second

patient was an HIV-positive man with AIDS who had a constitution—and not acquired—fissured tongue with HSV infection lesions that appeared as plaques on his tongue [14].

The current paper is a clinical review of atypical presentations of mucocutaneous HSV infection. A comprehensive assessment of the reported patients with HGG has been performed. In addition, to acknowledge the contribution of the first author—Marc E Grossman MD—on the original HGG manuscript, this paper also supports the suggestion that HGG be referred to as Grossman's geometric glossitis, especially since alliteration is a helpful memory aid in remembering unique conditions [12].

### **Epidemiology**

The characteristics of the 11 patients with HGG are presented in [Table 2](#) [5,7-11,13-15]. They ranged in age from 15 to 59 years (median, 37 years). The 6 men ranged in age from 15 to 52 years (median, 39 years) and the five women ranged in age from 27 to 59 years (median, 34 years).

The patients were either Caucasian (6 patients) or Hispanic (3 patients). Three men were Caucasian and two men were Hispanic. Three women were Caucasian and one woman was Hispanic. The race was not provided for the other patients.

### **Medical diseases**

Ten patients with HGG had one or more medical diseases. Human immunodeficiency virus seropositivity was the most common condition: three men and three women. Infection—either pneumonia (3 patients) or cryptococcosis (1 patient) or progressive multifocal leukoencephalopathy (1 patient) was also frequently observed. Some of the patients had a disease that result in the host becoming immunocompromised (such as acute myelogenous leukemia) or conditions that required acute or chronic treatment with immunosuppressive medications (such as bronchitis or pneumonitis or solid organ transplant recipient or systemic lupus erythematosus), [5,7-11,13-15].

### **Immunosuppressive treatment**

Eight patients were receiving treatment with one or more immunosuppressive agents. A systemic corticosteroid was being used in 6 patients. The man

who had a cardiac transplant was also receiving azathioprine and cyclosporine. The 15-year-old boy, who had leukemia, was receiving chemotherapy with multiple antineoplastic drugs [5,7-11,13-15].

### Immunocompromised patients

Herpetic geometric glossitis, in 1993, was initially observed in 5 HIV-infected patients [5]. A subsequent report noted HGG in another human immunodeficiency virus infected woman and a medication-induced immunosuppressed man who was a cardiac transplant patient [8]. Thereafter, it occurred in another immunocompromised individual—a boy with acute myelogenous leukemia who was receiving multiple chemotherapy agents [9].

However, in 2009, HGG was described in an immunocompetent woman who had viral pneumonitis [10]. A decade later, HGG was reported in a man with bronchiectasis and pneumonia who was not immunosuppressed; however, his tongue lesions appeared after starting prednisolone [13]. Eventually a third patient—a 30-year-old woman with no medical conditions who was not receiving any immunosuppressive treatment—was also observed to have HGG [15].

### Clinical presentation

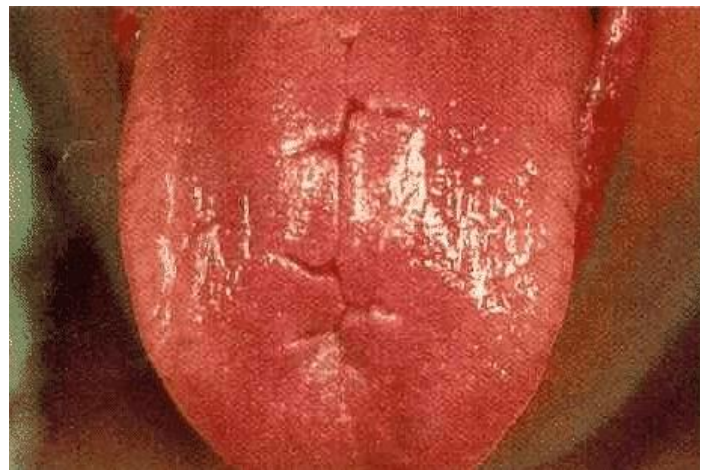
The appearance of HGG in the originally described 5 patients was identical. The surface of tongue was smooth and bright red. Extremely tender fissures were present on the tongue's dorsal surface. A prominent painful long longitudinal fissure was noted in the center of the tongue and multiple tender shorter fissures extended from the central fissure, in a branching pattern, toward the lateral sides of the tongue (**Figure 1**), [5].

Several of the subsequent patients with HGG had similar appearing tongues [7-10,15]. However, in addition to geometric shaped erosions, one man's tongue also had painful fissured plaques. All of his lesions regressed after he was treated with antiviral therapy [13].

Importantly, the fissures on the tongue were acquired and not constitutional. The fissures were not present prior to the HSV infection and they resolved after treatment with antiviral treatment.

Therefore, the acquired tongue lesions of an immunocompetent patient who had a constitutional and persistent fissured tongue—particularly, the new onset of herpes simplex virus-induced vegetative plaques that resolved after he was treatment with acyclovir—did not fulfill the criteria for HGG [14].

Tongue lesions in immunosuppressed individuals can be unique in appearance. Specifically, herpes simplex virus infection of the tongue in immunocompromised hosts can present as nodules or ulcers; in addition, they may have a concurrent bacterial infection [83-85]. Hence, the HSV-associated tongue lesions of an immunosuppressed man with acute myelogenous leukemia that appeared as painful ulcers on the tongue and palate



**Figure 1.** Herpetic geometric glossitis. Clinical presentation of herpetic geometric glossitis as painful linear fissure with a branched pattern on the dorsum of the tongue. A 27-year-old human immunodeficiency virus seropositive Hispanic woman, with a history of intravenous drug use, was hospitalized for a severe allergic reaction to trimethoprim-sulfamethoxazole with an associated pneumonitis which presented as acute respiratory decompensation on the third day of hospitalization; intravenous pentamidine and corticosteroids were started. She developed an extremely painful 5cm-long longitudinal fissure, with several tender smaller linear fissures branching from the central fissure, on the dorsal tongue on the sixth day of hospitalization. After the viral culture of the tongue fissure grew herpes simplex virus type 1, oral acyclovir (at a dose of 200 milligrams, 5 times day, for 10 days) was started; the pentamidine was stopped and the systemic corticosteroids were tapered. The pain had completely resolved and the fissures had almost healed after 10 days of acyclovir therapy. (From Marc E Grossman, Amy W Stevens, and Philip R Cohen. Brief report: herpetic geometric glossitis. *New England Journal of Medicine*, 1993;329:1859-1860. Copyright 1993 Massachusetts Medical Society. Reprinted with permission [5].)



and improved after famciclovir therapy did not fulfill the criteria for HGG [11].

Fissured tongue has also been referred to as cerebriform tongue, grooved tongue, plicated tongue, and scrotal tongue. It can occur idiopathically as a normal variant in individuals of all ages [10,38,40-47]. However, there is an extensive differential diagnosis of tongue fissures ([Box 1](#)), [5,7-10,13,15-82].

### Diagnosis of herpes simplex virus infection

Objective evidence was provided to confirm the diagnosis of herpes simplex virus infection in 9 patients with HGG; this included either a positive Tzanck preparation for multinucleated epithelial giant cells (2 patients) or a positive viral culture (7 patients). All viral cultures demonstrated herpes simplex virus type 1. The diagnosis of HGG was established subjectively in two patients; this was based not only on the clinical presentation of the tongue lesions, but also the favorable response of the symptoms and fissures to oral antiviral therapy [5,7-11,13-15].

### Herpes simplex virus infection sites

The tongue was the only affected site of HSV infection in six of the HGG patients. However, four patients had concurrent typical-appearing lesions of HSV infection on their lips. One patient also had herpetic lesions on his chest and face [5,7-11,13-15].

### Treatment

Oral antiviral agents with activity against HSV infection (such as acyclovir, famciclovir, and valacyclovir) is the treatment of choice for HGG [5,7-11,13-15]. Standard doses of the drugs are effective in both immunocompetent or immunosuppressed patients. However, one patient—the boy with acute myelogenous leukemia—required triple the regular dose of acyclovir to achieve resolution of his HGG [9].

### Response to therapy

All patients responded favorably to oral antiviral treatment. Tongue pain began to improve as early as 36 hours after initiating therapy; the pain had completely resolved in two to 14 days (median, 5 days). The lingual fissures also had healed within two to 14 days (median, 10 days), [5,7-11,13-15].

## Conclusion

Herpetic geometric glossitis is a distinctive manifestation of HSV type 1 infection on the dorsal tongue. It characteristically presents as an extremely painful longitudinal fissure in the center of the tongue; there is a branched pattern of fissures that extend bilaterally from the central linear fissure. Herpetic geometric glossitis was initially described in 1993; to date, 11 patients with HGG have been reported: 6 men and 5 women. Eight patients were immunocompromised. Indeed, concurrent or prior medical conditions and treatment with immunosuppressive agents were present in 7 patients; three patients only had one or more medical disorders and one patient had neither coexisting health problems or immunosuppressive medication treatment. Viral culture confirmed HSV type 1 infection in 7 patients; Tzanck preparation was positive for multinucleated giant cells in two patients and the diagnosis was based on not only the clinical appearance but also the resolution of all symptoms and lesions after treatment with antiviral therapy in two patients. Additional sites of mucocutaneous HSV infection were observed in 5 patients: lip alone (3 patients), lip and labial mucosa (1 patient), and face and chest (1 patient). All the patients' symptoms and lesions responded to treatment with oral antiviral therapy: acyclovir (9 patients), famciclovir (1 patient) or valacyclovir (1 patient). The lingual pain improved as early as 36 hours after initiating antiviral therapy; it resolved completely within two to 14 days (median, 5 days). Within two to 14 days (median, 10 days) after starting antiviral therapy, there was complete healing of the dorsal tongue fissures. In summary, HGG is a unique presentation of HSV type 1 infection that most commonly occurs on the dorsal tongue of immunocompromised patients and responds promptly and completely after initiation and adequate treatment with orally administered antiviral therapy such as acyclovir, famciclovir, or valacyclovir.

## Potential conflicts of interest

Dr. Cohen is a consultant for ParaPRO; however, this activity has no influence as a potential conflict of interest with regard to the manuscript. Therefore, the author declares no conflicts of interest.

## References

1. Chisholm C, Lopez L. Cutaneous infections caused by Herpesviridae: a review. *Arch Pathol Lab Med.* 2011;135:1357-1362. [PMID: 21970493].
2. Desai DV, Kulkarni SS. Herpes simplex virus: the interplay between HSV, host, and HIV-1. *Viral Immunol.* 2015;28:546-555. [PMID: 26331265].
3. Cather JC, Cohen PR. Herpes simplex virus type one infections. *J Gt Houst Dent Soc.* 1998;69:12-13. [PMID: 9571882].
4. Cohen PR. Tests for detecting herpes simplex virus and varicella-zoster virus infections. *Dermatol Clin.* 1994;12:51-68. [PMID: 8143385].
5. Grossman ME, Stevens AW, Cohen PR. Brief report: herpetic geometric glossitis. *N Engl J Med.* 1993;329:1859-1860. [PMID: 8247038].
6. Lam S, Lam BL. Herpetic geometric glossitis. *N Engl J Med.* 1994;330:1393. [PMID: 8018159].
7. Cohen PR, Grossman ME. Herpetic geometric glossitis. The authors reply. *N Engl J Med.* 1994;330:1393-1394. [PMID: 8018159].
8. Cohen PR, Kazi S, Grossman ME. Herpetic geometric glossitis: a distinctive pattern of lingual herpes simplex virus infection. *South Med J.* 1995;88:1231-1235.
9. Theriault A, Cohen PR. Herpetic geometric glossitis in a pediatric patient with acute myelogenous leukemia. *Am J Clin Oncol.* 1997;20:567-568. [PMID: 9391541].
10. Mirowski GN, Goddard A. Herpetic geometric glossitis in an immunocompetent patient with pneumonia. *J Am Acad Dermatol.* 2009;61:139-142. [PMID: 19539852].
11. Pereira CM, Souza CA, Correa MEP. Herpetic geometric glossitis: acyclovir resistant case in a patient with acute myelogenous leukemia. *Indian J Pathol Microbiol.* 2010;53:133-134. [PMID: 20090244].
12. Cohen PR. The "knife-cut sign" revisited: a distinctive presentation of linear erosive herpes simplex virus infection in immunocompromised patients. *J Clin Aesthet Dermatol.* 2015;8:38-42. [PMID: 26557219].
13. Altunisik Toplu S, Altunisik N, Bayindir Y. Herpetic geometric glossitis case: a rare oral herpetic appearance. *Adiyaman Univeritesi Saglik Bilimleri Dergisi (Health Sci J Adiyaman Univ).* 2019;5:1671-1674. [doi: 10.30569/adiyamansaglik.598574].
14. Rocha-Mendez LE, Ochoa-Hein E, Gutierrez-Gonzalez AN, Tarango-Martinez VM. Herpetic geometric glossitis presenting as vegetative plaques in the context of acquired immunodeficiency syndrome. *JAAD Case Rep.* 2021;12:64-66. [PMID: 34041334].
15. Iniguez-Flores EM, Espinoza-Rocha RA, Manzotti-Todriguez AC. Herpetic geometric glossitis in an immunocompetent patient. *Actas Dermosifiliogr.* 2023;114:458-459. [PMID: 35701246].
16. Valencia D, Linares J, Das S, Valencia V, Yatsynovich Y. Uncommon coronary abnormalities in a patient with discoid lupus erythematosus. *Int J Angiol.* 2020;29:260-262. [PMID: 33268978].
17. Menon SMR, Makkath NR. Myasthenia gravis masquerading as acute stroke: a case report. *Pan Afr Med J.* 2020;37:305. [33654524].
18. Verma GK, Tegta GR, Shama A, Kaur M, Sharma S. A rare case of extensive pemphigus vegetans. *Indian Dermatol Online J.* 2019;11:87-90. [PMID: 32055517].
19. Iwata M, Watanabe S, Tamaki K. Pemphigus vegetans presenting as scrotal tongue. *J Dermatol.* 1989;16:159-160. [PMID: 2778192].
20. Zampeli E, Kalogirou E-M, Piperi E, Mavragani CP, Moutsopoulos HM. Tongue atrophy in Sjogren syndrome patients with mucosa-associated lymphoid tissue lymphoma: autoimmune epithelitis beyond the epithelial cells of salivary glands? *J Rheumatol.* 2018;45:1565-1571. [PMID: 30008454].
21. Soto-Rojas AE, Villa AR, Sifuentes-Osornio J, Alarcon-Segovia D, Kraus A. Oral manifestations in patients with Sjogren's syndrome. *J Rheumatol.* 1998;25:906-910. [PMID: 9598889].
22. Crincoli V, Piancino MG, Iannone F, Errede M, Di Comite M. Temporomandibular disorders and oral features in systemic lupus erythematosus patients: an observational study of symptoms and signs. *Int J Med Sci.* 2020;17:153-160. [PMID: 32038098].
23. Rodriguez LV, Velasco JT, Vasconcellos RZ. Acquired paraneoplastic hypertrichosis lanuginosa associated with scleroderma. *Ann Dermatol Venereol.* 1990;117:605-610. [PMID: 2260800].
24. Sindhuphak W, Vibhagool A. Acquired hypertrichosis lanuginosa. *Int J Dermatol.* 1982;21:599-601. [PMID: 7160950].
25. Sunil G, Usha K. Symmetrical progressive erythro-keratoderma. *Indian J Dermatol Venereol Leprol.* 1999;65:191-192. [PMID: 20921653].
26. Tuzun Y, Mat MC, Serdaroglu S, Kotogyan A. Follicular atrophoderma with scrotal tongue. *Pediatr Dermatol.* 1987;4:328-331. [PMID: 3444783].
27. Fan W, Zhang Q, Song L. An unusual case of folliculitis spinulosa decalvans. *Cutis.* 2016;98:175-178. [PMID: 27814407].
28. Olenjnik M, Adamska K, Adamski Z, Dorocka-Bobkowska B. Oral health status of psoriatic patients managed with modern biological therapy. *Postepy Dermatol Alergol.* 2022;39:1151-1156. [PMID: 36686004].
29. Sobocka-Frankiewicz M, Rudnicka J, Iwanicka-Grzegorek E, Mielczarek A. Oral changes in patients with psoriasis. *Int J Dermatol.* 2023;62:604-610. [PMID: 35834660].
30. Afshar ZM, Barary M, Ebrahimpour S, et al. Pathophysiology and management of tongue involvement in COVID-19 patients. *Indian J Otolaryngol Head Neck Surg.* 2022;74:3235-3238. [PMID: 35013709].
31. Iranmanesh B, Khalili M, Amiri R, Zartab H, Aflatoonian M. Oral manifestations of COVID-19 disease: a review article. *Dermatol Ther.* 2021;34:e14578. [PMID: 33236823].
32. Vohra P. Oral and systemic manifestations in leprosy a hospital based study with literature review. *Indian J Dermatol.* 2022;67:631-638. [PMID: 36998854].
33. Vohra P, Rahman MSU, Subhada B, et al. Oral manifestation in leprosy: a cross-sectional study of 100 cases with literature review. *J Family Med Prim Care.* 2019;8:3689-3694. [PMID: 31803674].
34. Martins MD, Russo MP, Lemos JBD, et al. Orofacial lesions in treated southeast Brazilians leprosy patients: a cross-sectional study. *Oral Dis.* 2007;13:270-273. [PMID: 17448207].
35. King A, Nicol C, Rodin P. Late acquired syphilis. *Venereal Diseases.* London, Bailliere Tindall, 4<sup>th</sup> Ed., 1980, pp. 44-66.
36. Tobias N. Scrotal tongue and its inheritance. *Arch Dermatol.* 1945;52:266. [PMID: 21005895].
37. Shahbaz M, Kazmi F, Majeed HA, et al. Oral manifestations: a reliable indicator for undiagnosed diabetes mellitus patients. *Eur J Dent.* 2023;17:784-789. [PMID: 36220121].
38. Hamrah MH, Baghalian A, Ghadimi S, et al. The prevalence and correlates of fissured tongue among outpatients in Andkhoy City, Afghanistan: a cross-sectional study. *Clin Cosmet Investig Dent.* 2021;13:335-342. [PMID: 34345186].
39. Sudarshan R, Vijayabala GS, Samata Y, Ravikiran A. Newer classification system for fissured tongue: an epidemiological approach. *J Trop Med.* 2015;2015:262079. [PMID: 26457087].
40. Hong CHL, Dean DR, Hull K, et al. World workshop on oral medicine VII: relative frequency of oral mucosal lesions in children, a scoping review. *Oral Dis.* 2019;25:193-203. [PMID:

- 31034120].
41. Farman AG. Tongue fissures. A classification and comparative prevalence study among 825 European Caucasian and 605 Xhosa Negro school children. *J Biol Buccale*. 1976;4:349-364. [PMID: 1069731].
  42. Mahdani FY, Parmadiati AE, Ernawati DS, et al. Prevalence of oral normal variance in healthy elderly patients: a descriptive study on oral pseudo-lesions. *Int Arch Otorhinolaryngol*. 2022;26:e671-e675. [PMID: 36405462].
  43. Jainkittivong A, Aneksuk V, Langlais RP. Oral mucosal conditions in elderly dental patients. *Oral Dis*. 2002;8:218-223. [12206403].
  44. Ehsan H, Azimi S, Yosufi A, Yousufi R. The prevalence and significance of fissured tongue in Kabal City among dental patients. *Clin Cosmet Investig Dent*. 2023;15:21-29. [PMID: 36860622].
  45. Halperin V, Kolas S, Jefferis KR, et al. The occurrence of Fordyce spots, benign migratory glossitis, median rhomboid glossitis, and fissured tongue in 2,478 dental patients. *Oral Surg Oral Med Oral Pathol*. 1953;6:1072-1077. [PMID: 13088005].
  46. Rajeev V, Basheer SA, Elnager M, Karthik AK, Radhakrishnan AS. Cerebriform tongue. *J Pharm Bioallied Sci*. 2021;13:S868-S870. [PMID: 34447218].
  47. Feil ND, Filippi A. Frequency of fissured tongue (lingua plicata) as a function of age. *Swiss Dent J*. 2016;126:886-897. [PMID: 27808348].
  48. Kullaa-Mikkonen A. Familial study of fissured tongue. *Scand J Dent Res*. 1988;96:366-375. [PMID: 3166201].
  49. Yun SJ, Lee J-B, Kim S-J, Won Y, Lee S-C. Recurrent geographic tongue and fissured tongue in association with pregnancy. *J Eur Acad Dermatol Venereol*. 2007;21:287-289. [PMID: 17243991].
  50. Fisher BK, Linzon CD. Scrotal glans penis (glans penis plicatum) associated with scrotal tongue (lingua plicata). *Int J Dermatol*. 1997;36:762-763. [PMID: 9372351].
  51. Bakshi SS. Fissured tongue. *Cleve Clin J Med*. 2019;86:714. [PMID: 31710590].
  52. Beaven DW, Brooks SE. Tongue changes in congenital and developmental abnormalities. *Color Atlas of the Tongue in Clinical Diagnosis*. Ipswich, England, Wolfe Medical Publications LTD, 1988, pp. 203-215.
  53. King NM, Tong MC, Ling JY. The ectrodactyly-ectodermal dysplasia-clefting syndrome: a literature review and case report. *Quintessence Int*. 1994;25:731-736. [PMID: 9161252].
  54. Reddy MS, Manyam R, Babu MN, Saraswathi TR. Gingival fibromatosis with hemi-osseous hyperplasia of jaws, focal maxillary viral papillomatosis of gingiva, fissured tongue and congenitally missing anterior teeth: a case report and surgical management of a new syndrome. *Indian J Dent Res*. 2011;22:489-492. [PMID: 22048596].
  55. Kadakia N, Waghmare M, Gotmare S, Manoj R. Goldenhar syndrome in a young girl. *J Coll Physicians Surg Pak*. 2019;29:1108-1110. [PMID: 31659973].
  56. Esposito L, Poletti L, Maspero C, et al. Hyper-IgE syndrome: dental implications. *Oral Surg Oral Med Oral Pathol Oral Radiol*. 2012;114:147-153. [PMID: 22769403].
  57. Salamon T. Symmetrical interdigital hyperkeratosis of the hands with scrotal tongue and highly arched palate. *Dermatologica*. 1990;181:165-166. [PMID: 2242788].
  58. James J, Thekkeveetil AK, Vadakkepurayil K. Oral manifestations of Job's syndrome in a paediatric dental patient—a case report. *J Clin Diagn Res*. 2016;10:ZD04-ZD05. [PMID: 28050511].
  59. Levic ZM, Stefanovic BS, Nikolic MZ, Pisteljic DT. Progressive nuclear ophthalmoplegia associated with mental deficiency, lingua scrotalis, and other neurologic and ophthalmologic signs in a family. *Neurology*. 1975;25:68-71. [PMID: 1167409].
  60. Temtamy SA, Aglan MS, Ashour AM, et al. 3-M syndrome: a report of three Egyptian cases with review of the literature. *Clin Dysmorphol*. 2006;15:55-64. [PMID: 16531729].
  61. Aoun G, Skandri N, Ghattas H, Maksoud C. Melkersson-Rosenthal syndrome in a 38-year-old female patient: a rare case with complete triad. *Cureus*. 2022;14:e27427. [PMID: 36051736].
  62. Kuang W, Luo X, Wang J, Zeng X. Research progress on Melkersson-Rosenthal syndrome. *Zhejiang Da Xue Bao Yi Xue Ban*. 2021;50:148-154. [PMID: 34137235].
  63. De Serpa Pinto MVX, De Magalhaes MHCG, Nunes FD. Moebius syndrome with oral involvement. *Int J Paediatr Dent*. 2002;12:446-449. [PMID: 12452989].
  64. Du Z-F, Xu C-M, Zhao Y, et al. Two novel de novo mutations of KRT6A and KRT16 genes in two Chinese pachyonychia congenita pedigrees with fissured tongue or diffuse plantar keratoderma. *Eur J Dermatol*. 2012;22:476-480. [PMID: 22668561].
  65. Loddo S, Alesi V, Radio FC, et al. PPP1R21-related syndromic intellectual disability: report of an adult patient and review. *Am J Med Genet A*. 2020;182:3014-3022. [PMID: 32985083].
  66. Fardal O, Nevland K, Johannessen AC, Vetti HH. The PTEN hamartoma tumor syndrome: how oral clinicians may save lives. *Clin Adv Periodontics*. 2023;13:21-26. [PMID: 35352876].
  67. Scheper MA, Nikitakis NG, Sarlani E, Sauk JJ, Meiller TF. Cowden syndrome: report of a case with immunohistochemical analysis and review of the literature. *Oral Surg Oral Med Oral Pathol Oral Radiol Endod*. 2006;101:625-631. [PMID: 16632275].
  68. Basman A, Akay G, Peker I, et al. Dental management and orofacial manifestations of a patient with Robinow syndrome. *J Istanbul Univ Fac Dent*. 2017;51:43-48. [PMID: 28955595].
  69. Karthikeyani S, Thirumurthy VR, Yuvaraja BA. Dental management of Rapp-Hodgkin syndrome associated with oral cleft and hypodontia. *J Indian Soc Pedod Prev Dent*. 2016;34:192-195. [PMID: 27080974].
  70. Athappan G, Unnikrishnan A, Chengat V, et al. Touraine Solente Gole syndrome: the disease and associated tongue fissuring. *Rheumatol Int*. 2006;29:1091-1093. [PMID: 19050893].
  71. Al-Maweri S-A, Tarakji B, Al-Sufyani GA, Al-Shamiri HM, Gazal G. Lip and oral lesions in children with Down syndrome. A controlled study. *J Clin Exp Dent*. 2015;7:e284-e288. [PMID: 26155347].
  72. Daneshpazhooh M, Nazemi TM-J, Bigdeloo L, Yoosefi M. Mucocutaneous findings in 100 children with Down syndrome. *Pediatr Dermatol*. 2007;24:317-320. [PMID: 17542890].
  73. Dourmishev AL, Dourmishev LA, Schwartz RA, Janniger CK. Waardenburg's syndrome with facial palsy and lingua plicata: is that a new type of disease? *Cutis*. 1999;63:139-141. [PMID: 10190061].
  74. Desmons F, Bombart-Thoreux M, Struyve J. Elf facies in congenital idiopathic hypercalcemia macrocheilitis fissured tongue. *Bull Soc Fr Dermatol Syphiligr*. 1970;77:353-355. [PMID: 5510724].
  75. Ghapanchi J, Rezazadeh F, Kamali F, et al. Oral manifestations of asthmatic patients. *J Pak Med Assoc*. 2015;65:1226-1227. [PMID: 26564298].
  76. Owosho AA, Buraczewski T, Summersgill KF. Clinicopathologic review: linear fissured ulcerations in the oral cavity. *Pa Dent J (Harrishb)*. 2015;82:16-19. [PMID: 26591832].
  77. Meng P, Du W, Xu L, et al. *Lactobacillus* treatment as adjuvant for geographic tongue and fissured tongue with gastritis: case report. *Ann Transl Med*. 2023;11:186. [PMID: 36923092].
  78. Song J, Wang Q, Xu X, Lv C. Predictive value of fissured tongue in functional dyspepsia combined with depression. *Gastroenterol Res Pract*. 2019;2019:4596560. [PMID: 31316559].
  79. Guggenheimer J, Close JM, Egtesad B, Shay C. Characteristics of

- oral abnormalities in liver transplant candidates. *Int J Organ Transplant Med.* 2010;1:107-113. [PMID: 25013575].
80. Diaz-Ortiz ML, Mico-Lioren JM, Gargallo-Albiol J, et al. Dental health in liver transplant patients. *Med Oral Patol Cir Bucal.* 2005;10:72-76; 66-72. [PMID: 15627910].
81. Gulec AT, Haberal M. Lip and oral mucosal lesions in 100 renal transplant recipients. *J Am Acad Dermatol.* 2010;62:96-101. [PMID: 19926164].
82. Gonul M, Gul U, Kaya I, et al. Smoking, alcohol consumption and denture use in patients with oral mucosal lesions. *J Dermatol Case Rep.* 2011;5:64-68. [PMID: 22408705].
83. Kurzrock R, Auber M, Mavligit GM. Cimetidine therapy of herpes simplex virus infections in immunocompromised patients. *Clin Exp Dermatol.* 1987;12:326-331. [PMID: 3446417].
84. Cohen PR, Kurzrock R. Tongue lesions in the acquired immunodeficiency syndrome. *Cutis.* 1987;40:406-409. [PMID: 38173151].
85. Cohen PR, Kurzrock R. Herpes simplex virus infections and cimetidine therapy. *J Am Acad Dermatol.* 1988;19:762-763. [PMID: 3183099].



**Table 1.** History of reported cases of herpetic geometric glossitis<sup>a</sup>.

Author (Year)	Comment	Ref
Grossman et al. (1993)	A case series of five immunocompromised HIV-positive patients (three men and two women) whose HSV-1 infection presented as extremely tender, linear fissure with a sticking geometric pattern on the dorsum of the tongue. The researchers introduced the herpetic geometric glossitis to describe this unique presentation of HSV infection of the tongue.	[5]
Lam, Lam (1994)	A letter-to-the-editor commenting that the longitudinal, crossed, or branched geometric patterns of HGG are similar in morphology to the dendrite—the characteristic, HSV infection-induced, branching pattern of the corneal epithelium. The authors speculated that the pathogenesis of HGG and corneal HSV dendrites had a common underlying mechanism.	[6]
Cohen, Grossman (1994)	The response to the letter-to-the-editor which included a succinct table that compared the characteristics of HGG and dendritic keratitis. The researchers concurred that based upon the similar lesion morphology of HGG and corneal HSV dendrites, it was reasonable to postulate that the mucosal manifestations of HSV infection at both sites had a common underlying mechanism.	[7]
Cohen et al. (1995)	Two case reports of HGG in immunocompromised patients: a male cardiac transplant recipient and an HIV-positive woman. The features of these two individuals and the previously described five HGG patients are summarized and the differential diagnosis of linear tongue fissures is presented.	[8]
Theriault, Cohen (1997)	A case report of an immunocompromised HIV-seronegative boy with AML who developed HHG while on receiving oral acyclovir for an upper lip HSV-1 infection-related ulcer; his HSV infection-related painful fissured tongue completely resolved within five days after the dosage of oral acyclovir was tripled from 200 milligrams five times daily to 600 milligrams five times daily.	[9]
Mirowski, Goddard (2009)	A case report of HHG occurring in an immunocompetent woman with viral pneumonia. The investigators emphasize that HHG is not restricted to only immunosuppressed patients but can also occur in immunocompetent individuals.	[10]
Pereira et al. (2010)	A case reported as HHG in an immunocompromised man with AML; his “painful ulcers on the tongue and palate” were resistant to acyclovir (325mg three times daily for 17 days). However, there was marked improvement without recurrence after subsequent treatment with famciclovir (500mg twice daily for five days). The morphology of the clinical tongue lesions (ulcers) does not fulfill the criteria for HHG.	[11]
Cohen (2015)	The initial paragraph in the discussion section of this case report and review highlights the features of HHG and refers to this unique manifestation of herpes simplex virus as Grossman’s geometric glossitis.	[12]
Altunisik, Toplu et al. (2019)	A case report of HHG in a man with bronchiectasis and pneumonia after initiating treatment with systemic prednisolone. The lesions were not only geometric shaped erosions, but also fissured and painful plaques; all lesions regressed after 14 days of valacyclovir.	[13]
Rocha-Mendez et al. (2021)	A case reported as HHG presenting as “vegetative plaques...on a constitutional fissured tongue” in an HIV-infected man with AIDS. He was treated with acyclovir (400mg very eight hours for ten days); symptoms resolved in 48 hours and there was complete remission within six days. The morphology of the clinical tongue lesions (vegetative plaques) does not fulfill the criteria for HHG and the fissured tongue in HHG is acquired—not constitutional.	[14]
Iniguez-Flores et al. (2022)	A case report of HGG in an immunocompetent woman. The investigators emphasize that HHG should be considered in all patients with painful glossitis.	[15]
Cohen (2024)	Clinical review of atypical presentations of mucocutaneous HSV infection. As a tribute to the first author of the original paper regarding this unique morphologic variant of HSV on the tongue and since alliteration aids in remembering conditions, it might be reasonable that HGG be referred to as Grossman’s geometric glossitis.	CR

<sup>a</sup>The cases reported by Pereira et al. [11] and Rocha-Mendez et al. [14] do not fulfill the morphologic criteria of HGG.

CR, current report; HGG, herpetic geometric glossitis; HIV, human immunodeficiency virus; HSV, herpes simplex virus; HSV-1, herpes simplex virus type 1; Ref, reference; &, and.

**Table 2.** Characteristics of patients with herpetic geometric glossitis<sup>a</sup>.

C	A R S	Medical diseases ITx	IC	Dx of HSVI HSV Sero	Other HSVI sites	Txment	Response to txment	Refs
1	15 Ca M	<u>AML</u> DCTER	+	<u>VC+</u> HSV-1	Lip	PO Acy: 600mg 5x daily	Resolved within 5 days	[9]
2	27 Hp F	<u>HIV+, T-SA</u> Corticosteroids	+	<u>VC+</u> HSV-1	None	PO Acy: 200mg 5x daily	D10, pain -, fissure ah	[5], C4
3	29 Ca M	<u>Crypto, HIV+</u> None	+	<u>VC+</u> HSV-1	Lip	PO Acy: 200mg 5x daily	D2, pain- D12, LL healed	[5], C1
4	30 NS F	<u>None</u> None	-	<u>TzPrep+</u> NDet	Lip labial mucosa	PO Acy: 400mg 3x daily	D10, pain- & LL healed	[15]
5	34 Ca F	<u>DILS, HIV+</u> Prednisone	+	<u>Clinical</u> NDet	None	PO Acy: 200mg 5x daily	D2, pain- More txment, LL healed	[7], [8], C2
6	37 Hp M	<u>HIV+, PCP, SLE</u> Prednisone	+	<u>VC+</u> HSV-1	None	PO Acy: 200mg 5x daily	D12, fissure healed	[5], C2
7	41 Hp M	<u>AL, DKA, HIV+, Pancreatitis</u> None	+	<u>VC+</u> HSV-1	None	PO Acy: 200mg 5x daily	LL and symptoms resolved	[5], C3
8	49 Ca F	<u>HIV+, PML</u> Dexamethasone	+	<u>VC+</u> HSV-1	None	PO Acy: 200mg 5x daily	D3, LL & symptoms healed	[5], C5
9	50 NS M	<u>Bronch, Pneum</u> Prednisolone	-	<u>Clinical</u> NDet	None	PO Val: 1000mg 2x daily	D14, all LL improved	[13]
10	52 Ca M	<u>CVA, SOTR, AZA, CYA</u> Prednisone	+	<u>VC+</u> HSV-1	Chest Face	PO Acy: 200mg 5x daily	Pain and fissures completely resolved	[7], [8], C1
11	59 Ca F	<u>CAD, ED, HL, LH, OP, Pneum, PUD, TD, UC</u> None	-	<u>TzPrep+</u> NDet	Lip	PO Fam: 250mg 2x daily	36 hours, pain decreased D5, pain-	[10]

<sup>a</sup>Two individuals reported to have herpetic geometric glossitis were not included in this table of bonified cases since the morphology of the patient's HSV infection tongue lesions was not consistent with that of herpetic geometric glossitis [11,14].

A, age in years; Acy, acyclovir; ah, almost healed; AZA, azathioprine; Bronch, bronchiectasis; C, case; Ca, Caucasian; CAD, coronary artery disease; Crypto, cryptococcal meningitis; CVA, cerebrovascular accident; CYA, cyclosporin a; D, day; DCTER, decadron, 6-thioguanine, cytarabine, etoposide, and daunomycin; Dx, diagnosis; ED, esophageal dysmotility; F, female; Fam, famciclovir; HIV, human immunodeficiency virus; HL, hyperlipidemia; Hp, Hispanic; HSV, herpes simplex virus; HSV-1, herpes simplex virus-type 1; HSVI, herpes simplex virus infection; IC, immunocompromised; ITx, immunosuppressive treatment; LH, labial herpes (recurrent); LL, lingual lesions; M, male; MD, medical diseases; mg, milligrams; NDet, not determined; NS, not stated; OP, osteoporosis; PCP, Pneumocystis carinii pneumonia; PML, progressive multifocal leukoencephalopathy (with cortical blindness); Pneum, pneumonia; PO, oral; Pred, prednisone; PUD, peptic ulcer disease; R, race; Refs, references; S, sex; Sero, serotype; SLE, systemic lupus erythematosus (with nephritis); SOTR, solid organ (heart) transplant recipient; TD, thyroid disease (with multinodular goiter); T-SA, trimethoprim-sulfamethoxazole allergy with pneumonitis; Txment, treatment; TzPrep, Tzanck preparation; UC, ulcerative colitis; Val, valacyclovir; VC, viral culture; X, times; +, positive; -, negative; &, and

**Box 1. Differential diagnosis of tongue fissures<sup>a</sup>.****Autoimmune diseases**

Discoid lupus erythematosus [16]  
 Myasthenia gravis [17]  
 Pemphigus vegetans [18,19]  
 Sjogren syndrome [20,21]  
 Systemic lupus erythematosus [22]  
 Cutaneous conditions  
 Acquired (paraneoplastic) hypertrichosis lanuginosa [23,24]  
 Erythrokeratoderma (symmetric progressive), [25]  
 Follicular atrophoderma [26]  
 Folliculitis spinulosa decalvans [27]  
 Psoriasis [28,29]

**Infectious diseases**

COVID-19 [30,31]  
 Herpes simplex virus [5,7-10,13,15]  
 Leprosy [32-34]  
 Syphilis (tertiary), [35]

**Metabolic disorders**

Acromegaly [36]  
 Diabetes [37-39]

**Normal variant**

Children [40,41]  
 Elderly [42,43]  
 Idiopathic [10,44,45]  
 Men [38,46,47]  
 Older individuals [47]

**Other**

Familial [36,48]  
 Pregnancy [49]  
 Scrotal glans penis [50]  
 Vitamin deficiencies [46,51]

**Syndromes**

Chromosome 11 disorder [52]  
 Ectrodactyly-ectodermal dysplasia and clefting syndrome [53]  
 Gingiva fibromatosis syndrome [54]  
 Goldenhar syndrome<sup>b</sup> [55]  
 Hyper-IgE syndrome [56]  
 Interdigit hyperkeratosis syndrome<sup>c</sup> [57]  
 Job syndrome [58]  
 Levic syndrome<sup>d</sup> [59]  
 3-M syndrome [60]  
 Melkersson-Rosenthal syndrome [61,62]  
 Moebius syndrome [63]  
 Pachyonychia congenita [64]  
 PPP1R21 syndrome<sup>e</sup> [65]  
 PTEN hamartoma tumor syndrome<sup>f</sup> [66,67]  
 Rabinow syndrome [68]  
 Rapp-Hodgkin syndrome [69]  
 Touraine Solente Gole syndrome [70]

Trisomy 21<sup>g</sup> [71,72]  
 Trisomy 46 [52]  
 Waardenburg syndrome [73]  
 William syndrome<sup>h</sup> [74]

**Systemic conditions**

Asthma [75]  
 Crohns disease [76]  
 Gastritis [77,78]  
 Hypertension [39]  
 Pernicious anemia [51]

**Tobacco**

Smoking [47]  
 Smokeless tobacco [38]

**Transplant patients**

Liver transplant candidates [79,80]  
 Renal transplant recipients [81]

**Trauma**

Dentures [82]  
 Not otherwise specified [8]

<sup>a</sup>A tongue that has fissures have been referred to as cerebriform tongue, fissured tongue (lingua fissurata), grooved tongue, plicated tongue (lingua plicata), and scrotal tongue.

<sup>b</sup>This syndrome is also referred to as oculo-auriculo-vertebral syndrome.

<sup>c</sup>This syndrome includes symmetric interdigitate hyperkeratosis of the hands, scrotal tongue, and highly arched palate.

<sup>d</sup>This syndrome is also referred to as ophthalmoplegia-intellectual disability-lingua scrotalis syndrome.

<sup>e</sup>This syndrome includes neurodevelopmental disorder with hypotonia, facial dysmorphism, brain abnormalities, and fissured tongue.

<sup>f</sup>This also includes Cowden syndrome.

<sup>g</sup>This syndrome is also referred to as Down syndrome.

<sup>h</sup>This syndrome is also referred to as elf facies syndrome.

COVID-19, coronavirus disease 2019; IgE, immunoglobulin E; PPP1R21, protein phosphatase one regulatory subunit 21; PTEN, phosphatase and tensin homolog;